



Kanan Shah

Objectives of the session

- Know about veins of the lower limb
- Able to write Short note on it

VEINS OF LOWER LIMB

THREE DISTINGUISHABLE
SETS

- **SUPERFICIAL VEINS-**

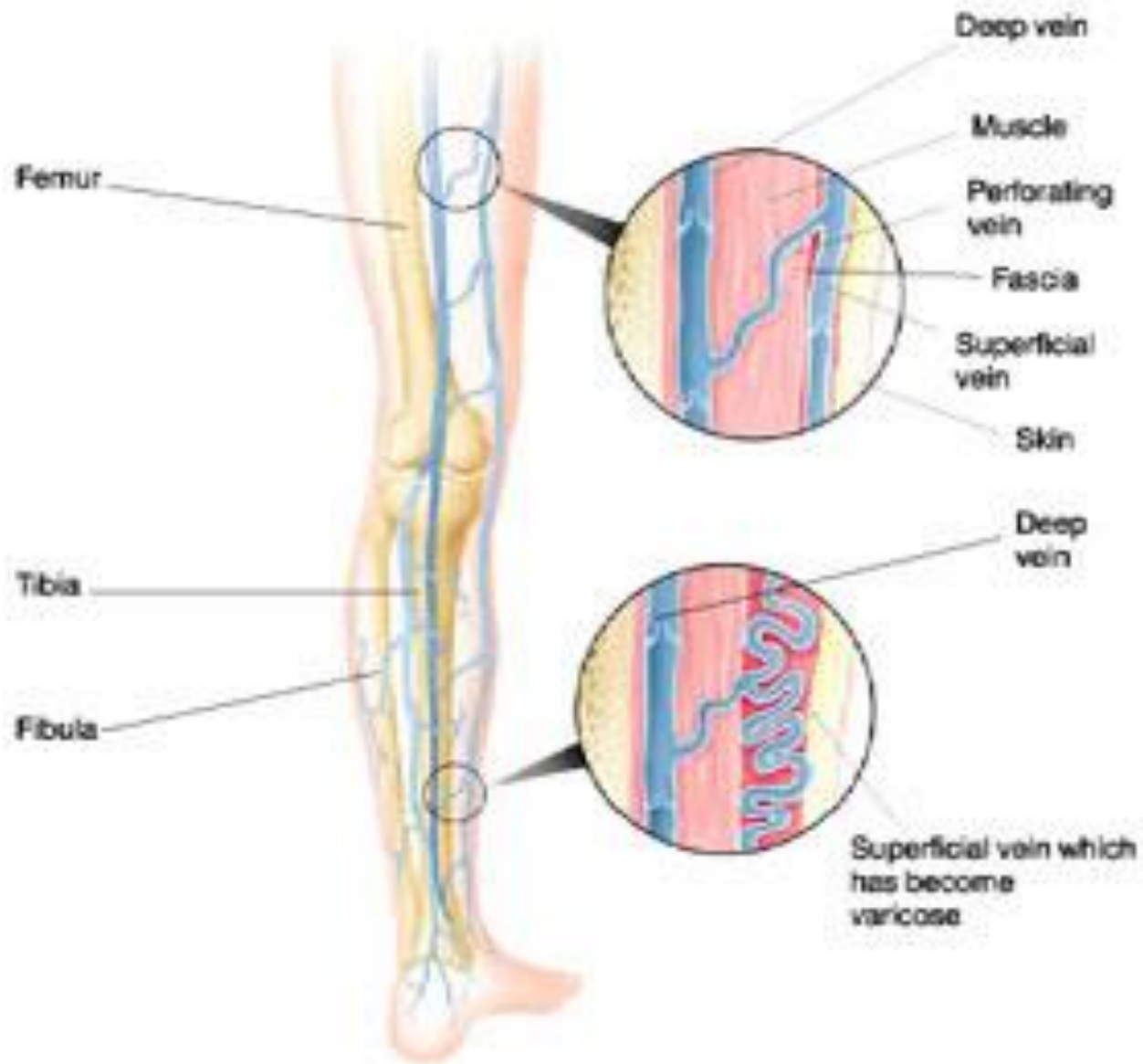
 - Great Saphenous Vein

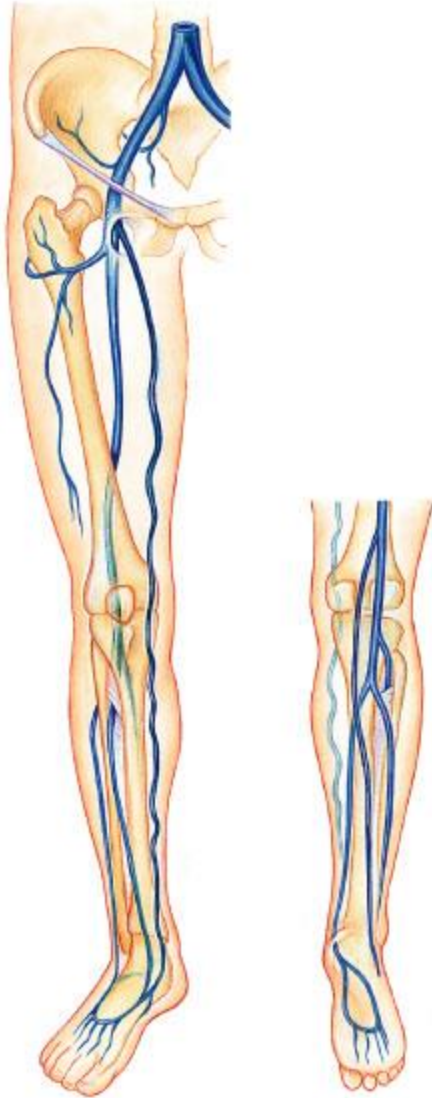
 - Small Saphenous Vein

- **DEEP VEINS-**

 - Venae Comitants accompanying
Tibial, Peroneal, Popliteal, Femoral
artery

- **PERFORATING VEINS**



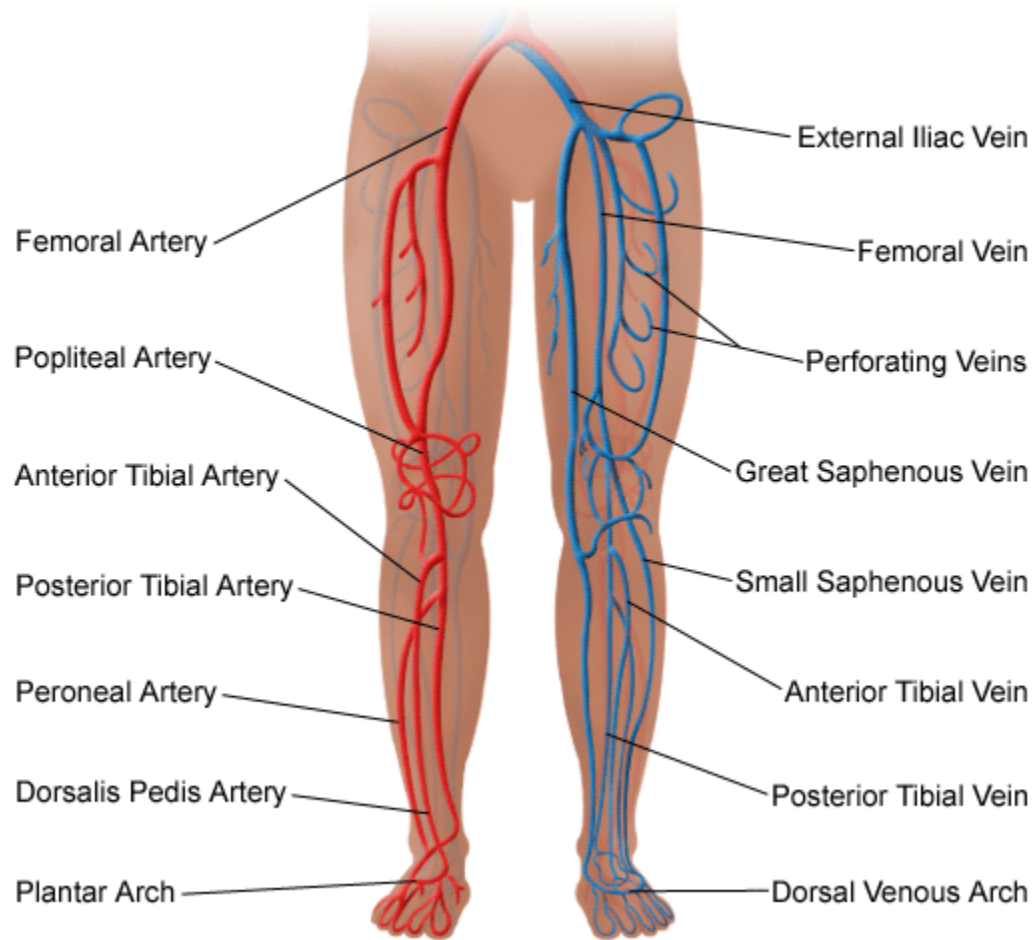


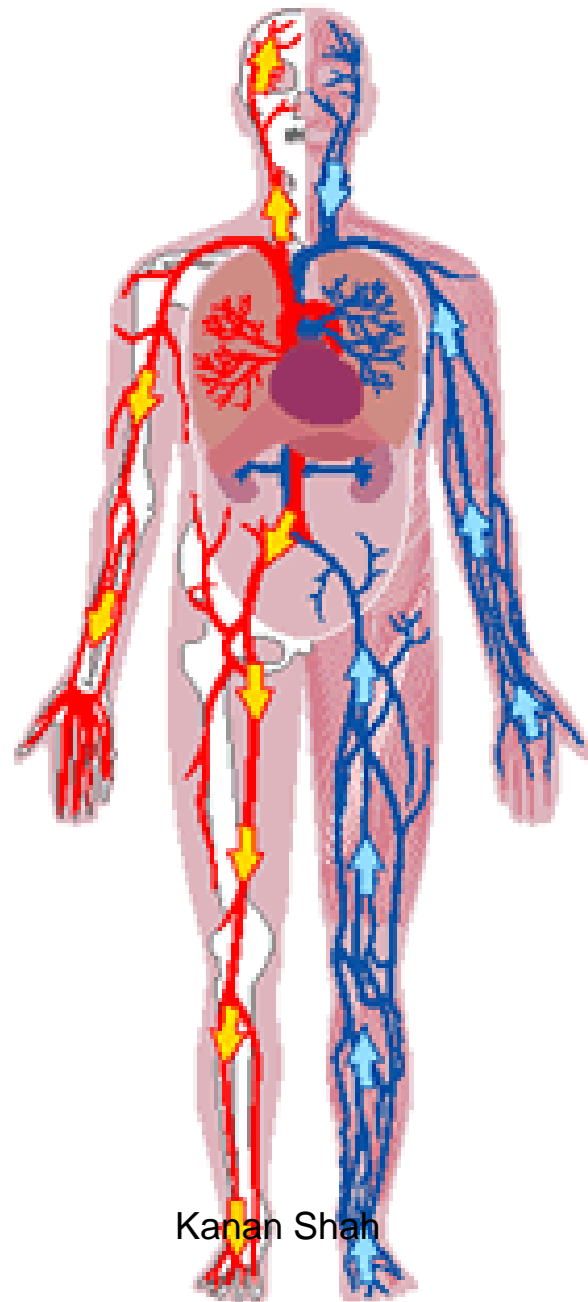
(b)

(c)

Copyright © 2004 Pearson Education, Inc., publishing as Benjamin Cummings.

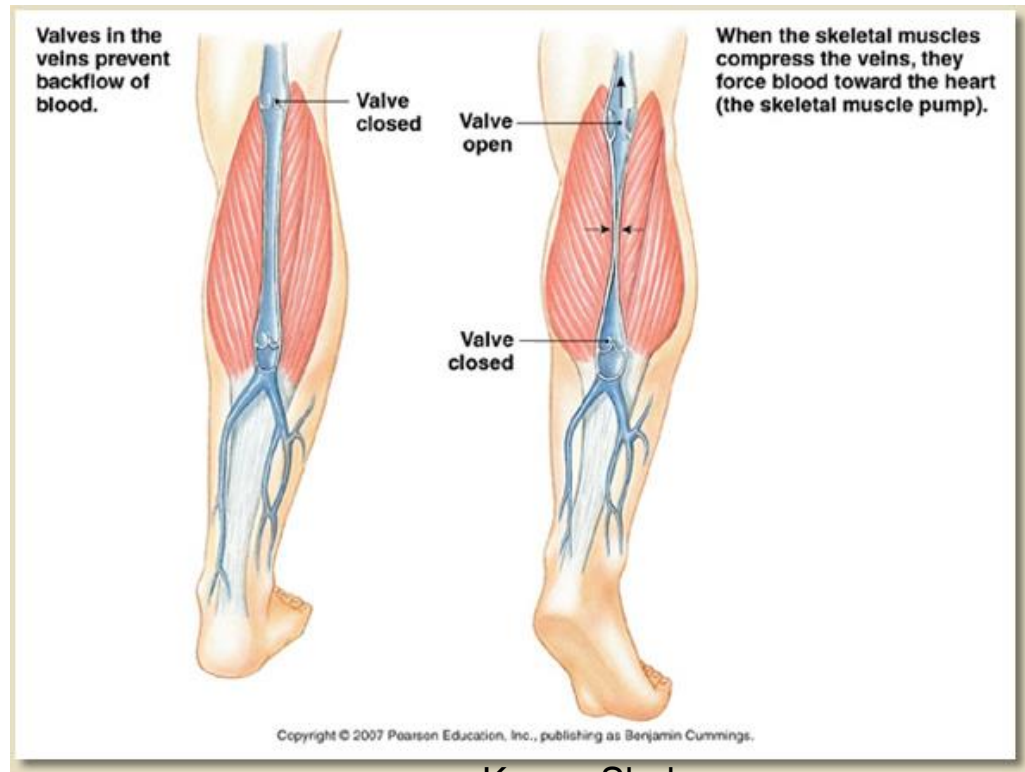
Arterial and Venous Circulation of the Legs






FACTORS HELPING VENOUS RETURN

- IN UPRIGHT POSITION
 - CALF PUMP



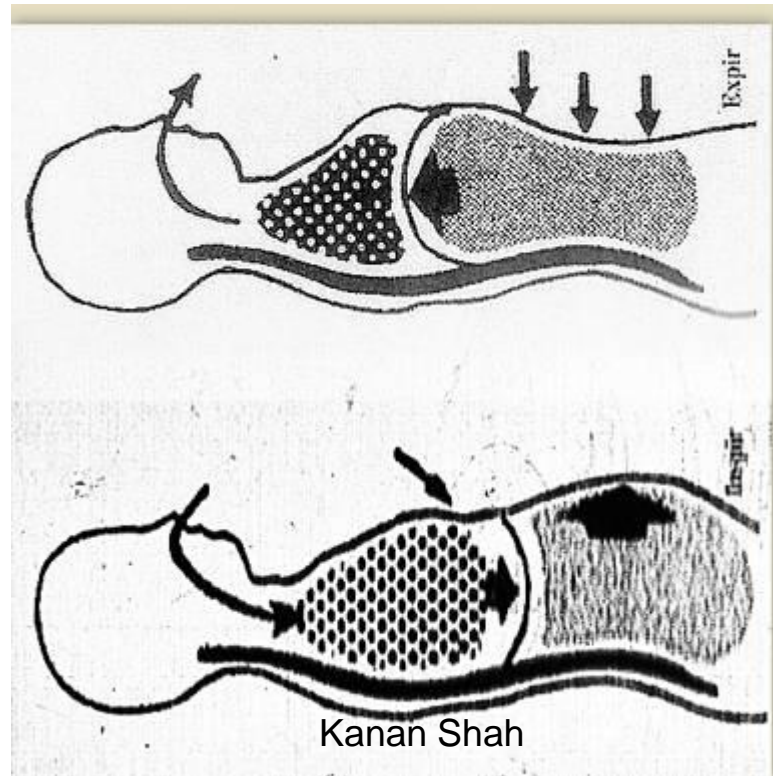
- TRANSMITTED PULSATION
- ARRANGEMENT OF VALVES IN THE VEINS



Kanan Shah

IN RECUMBENT POSITION

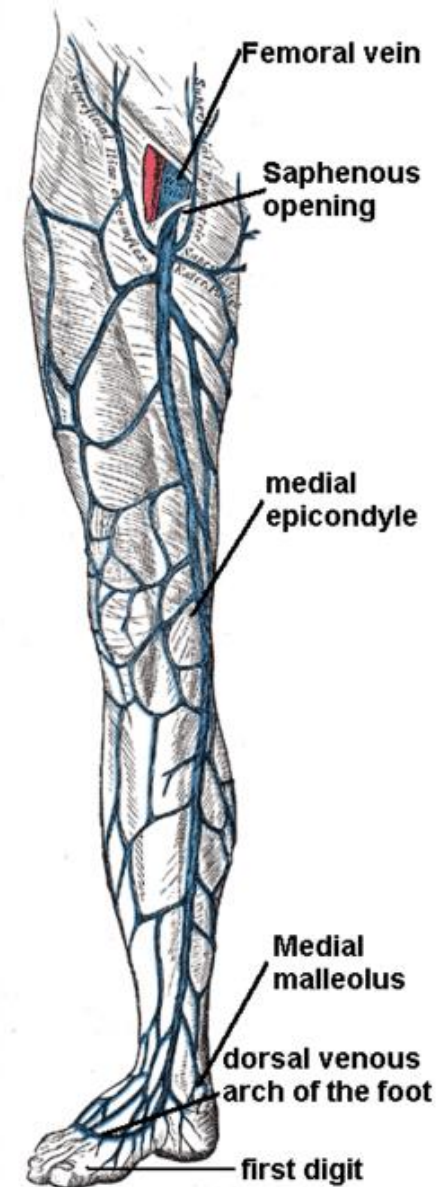
-CONTRACTION OF
THE HEART



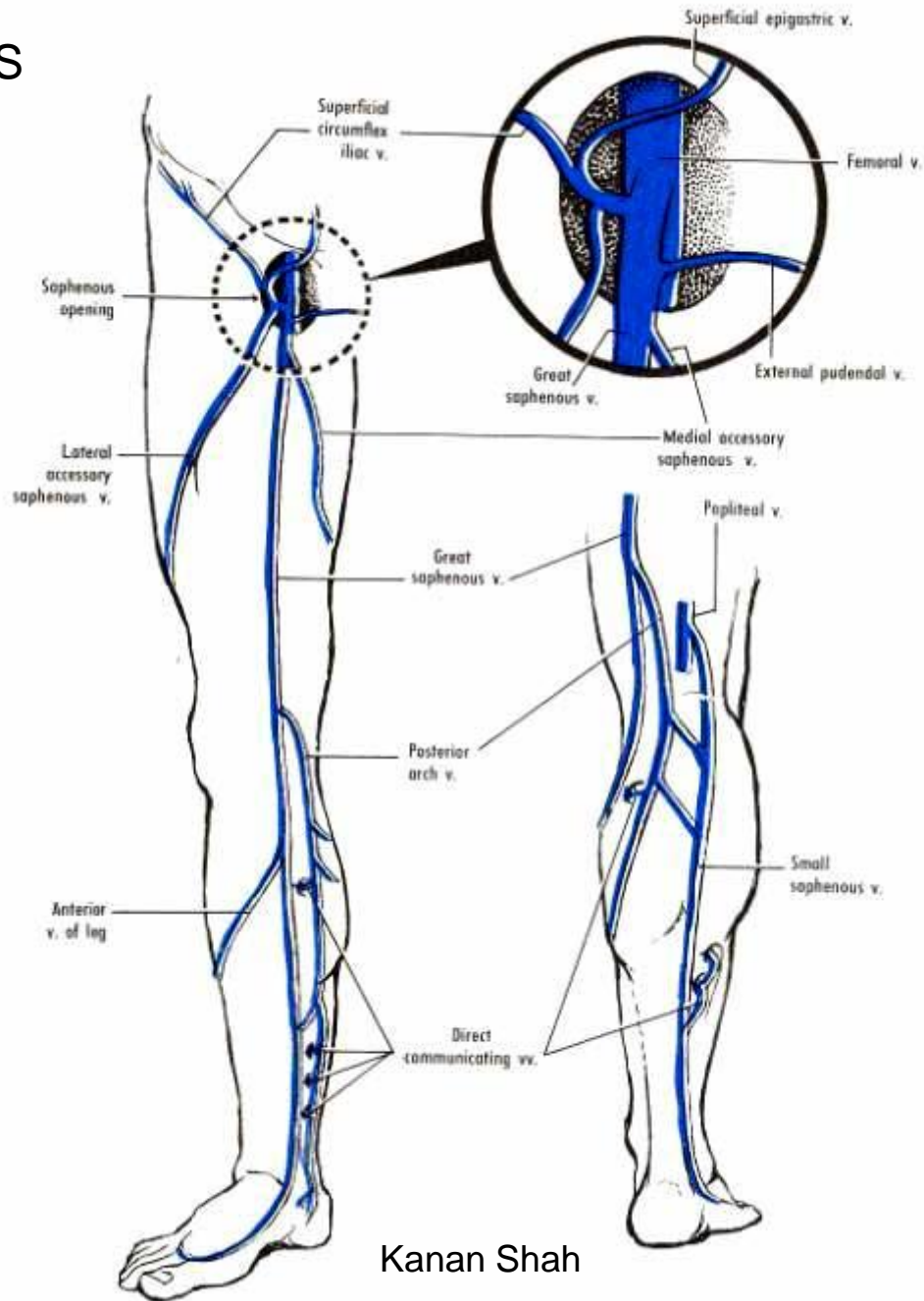
-SUCTION ACTION OF
THE DIAPHRAGM

GREAT SAPHENOUS VEIN

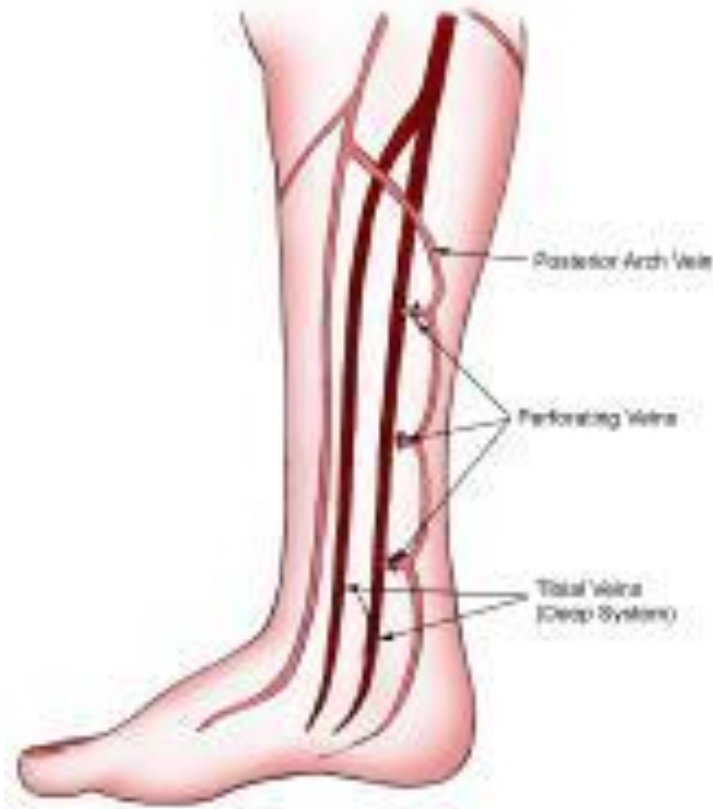- COURSE
- TRIBUTARIES
- APPLIED ANATOMY



•TRIBUTARIES

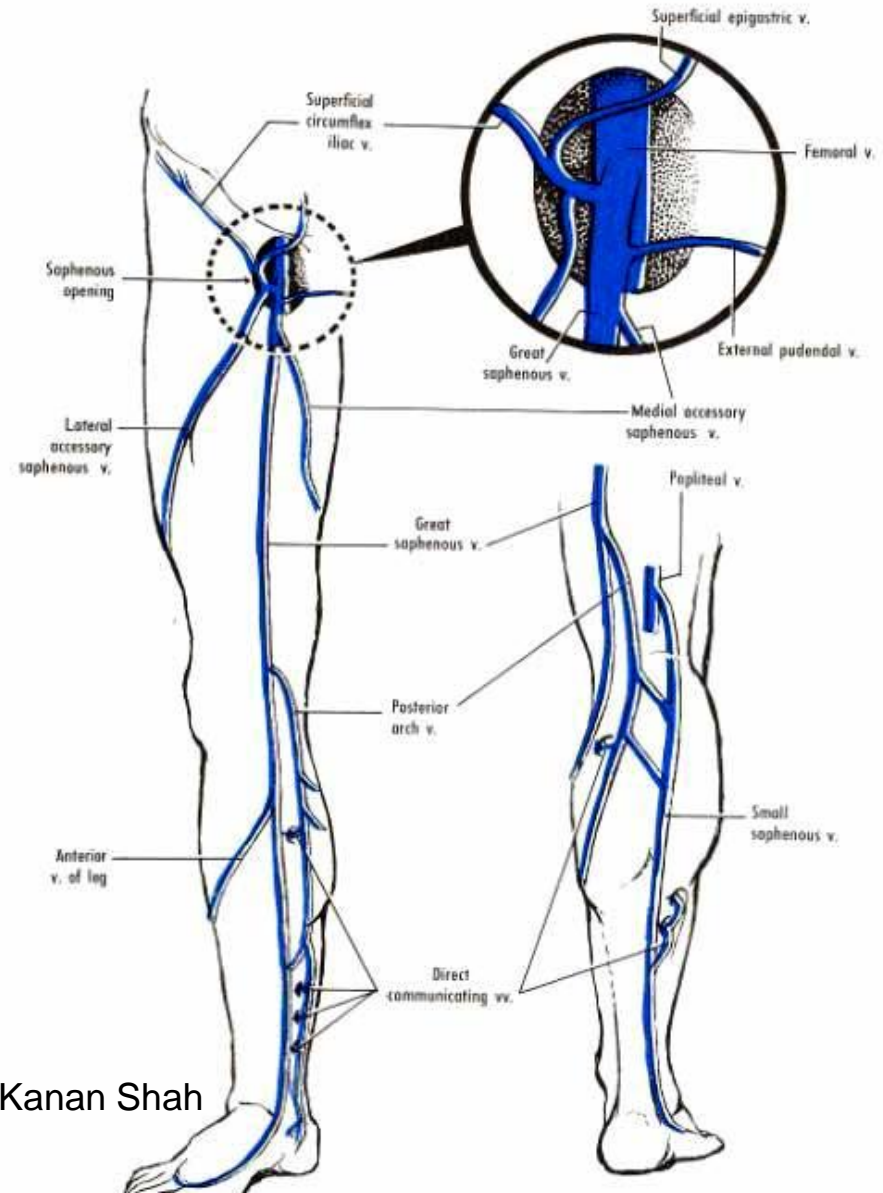


PERFORATORS

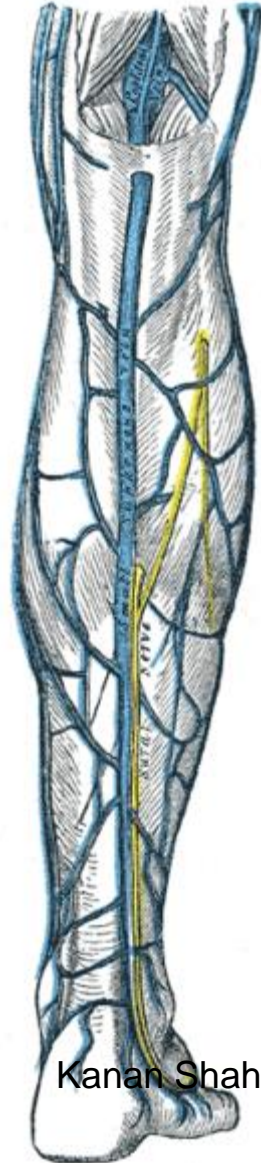


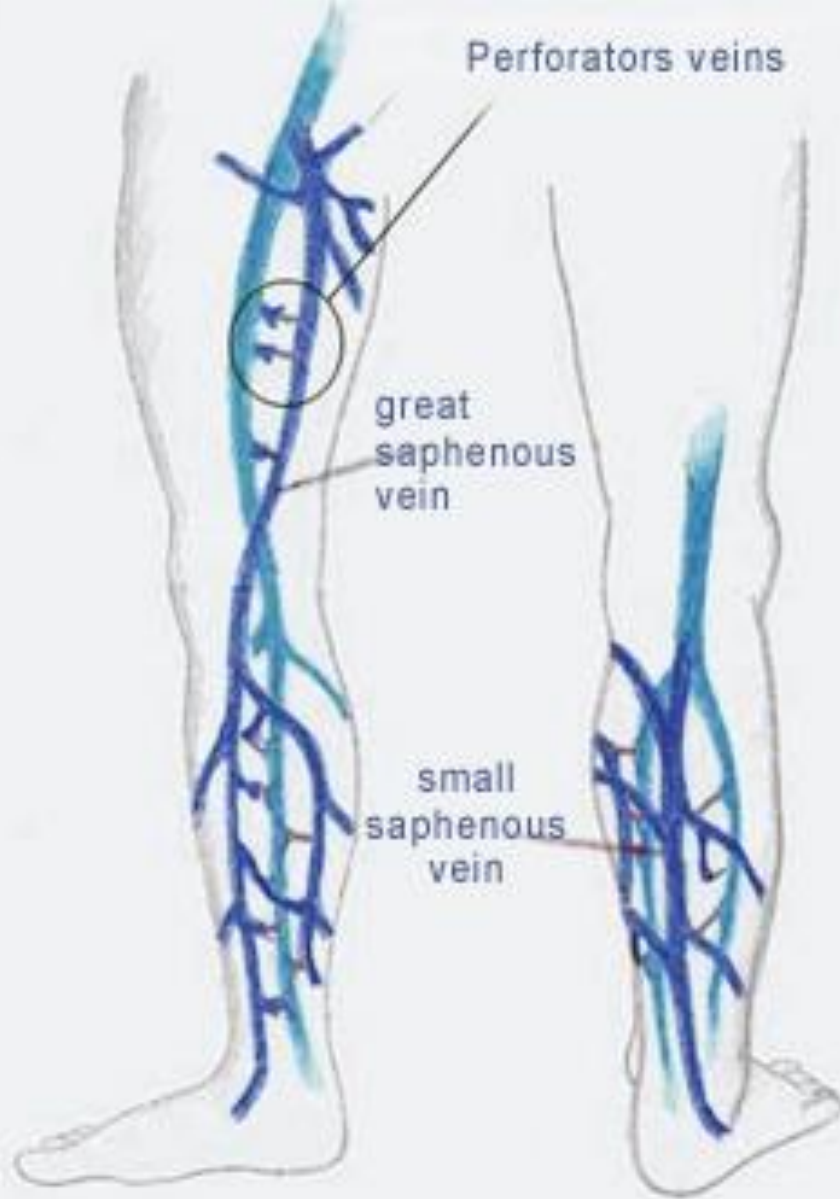
SMALL SAPHENOUS VEIN

- COURSE
- 7—13 Valves



SMALL SAPHENOUS VEIN



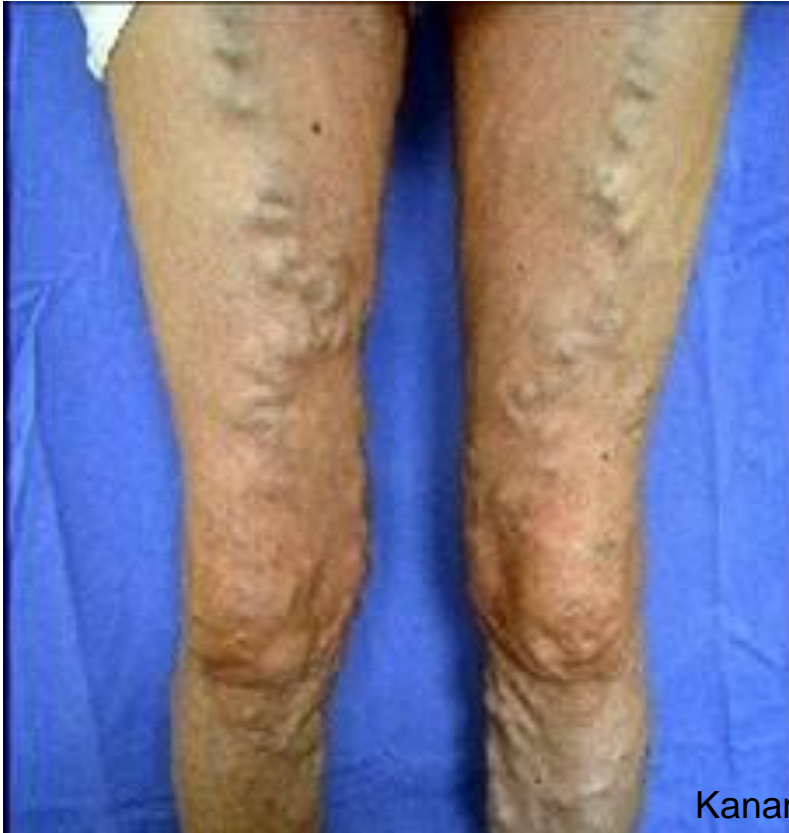

Blue: Deep veins
Dark blue: Superficial veins

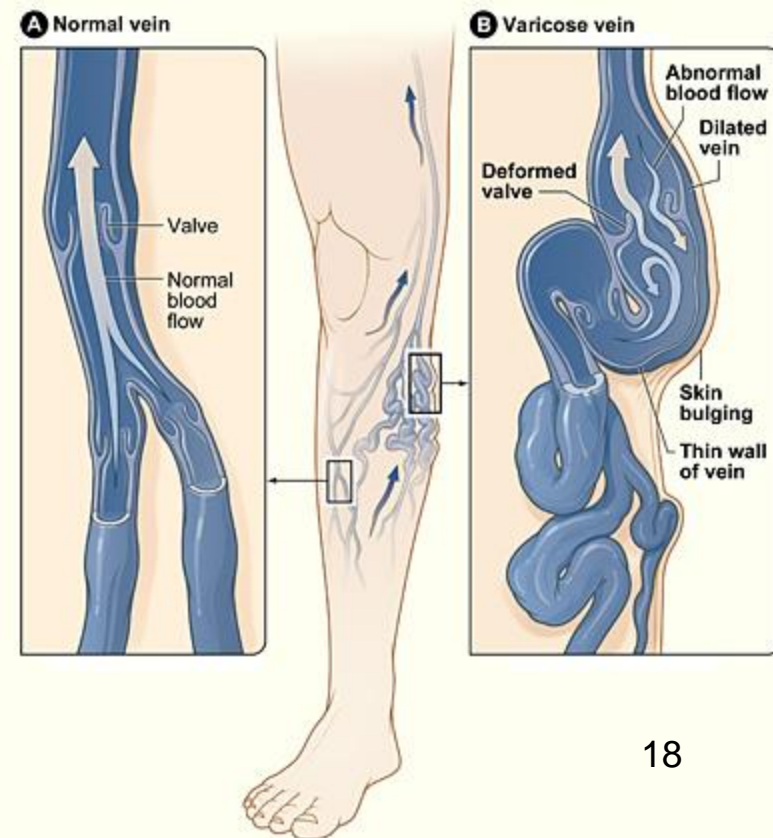
Kanap Shah

APPLIED ANATOMY

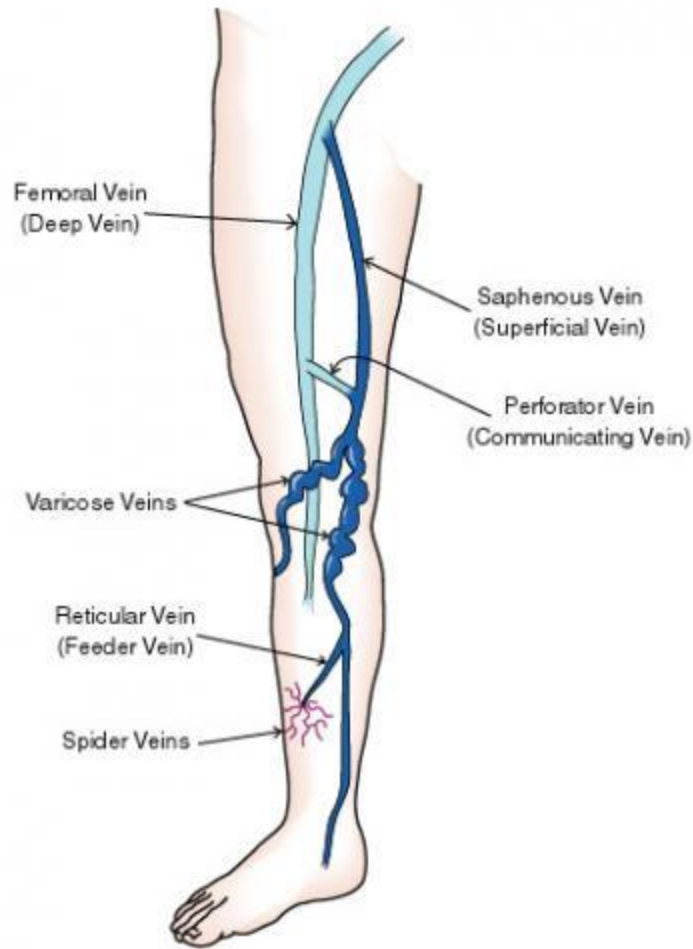
- Varicose veins –
Superficial veins are dilated & tortuous



Kanan Shah

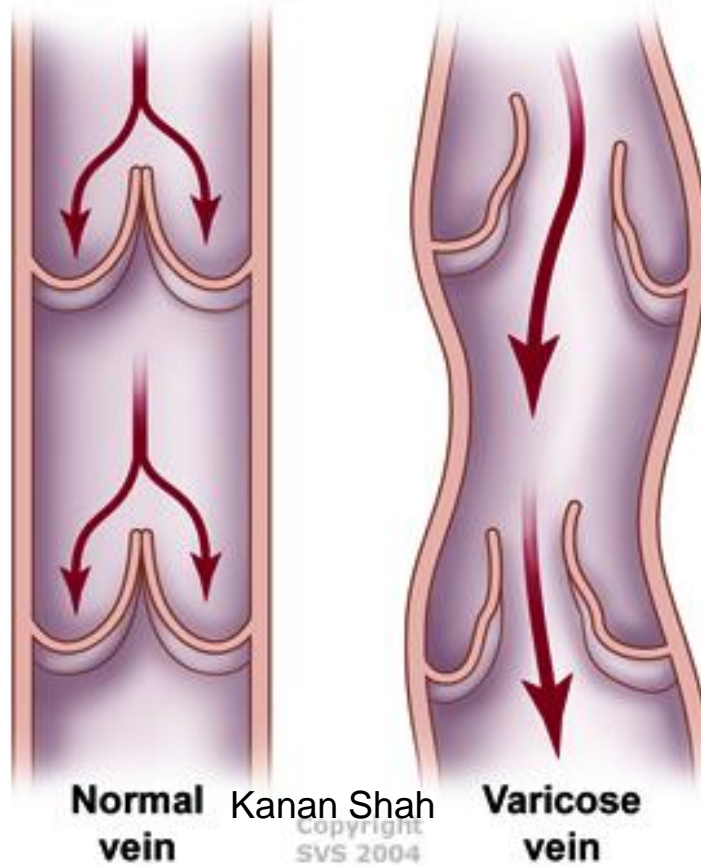


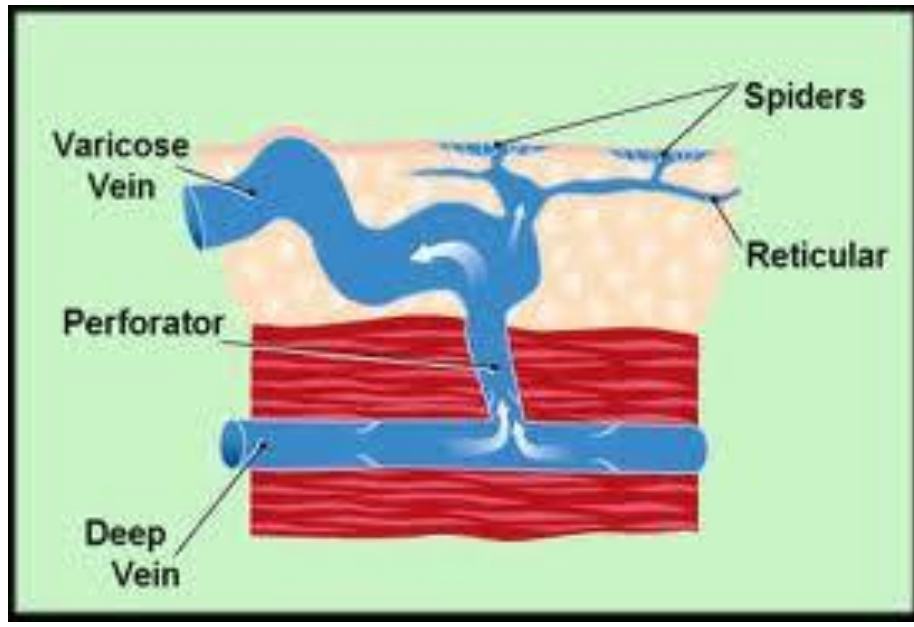
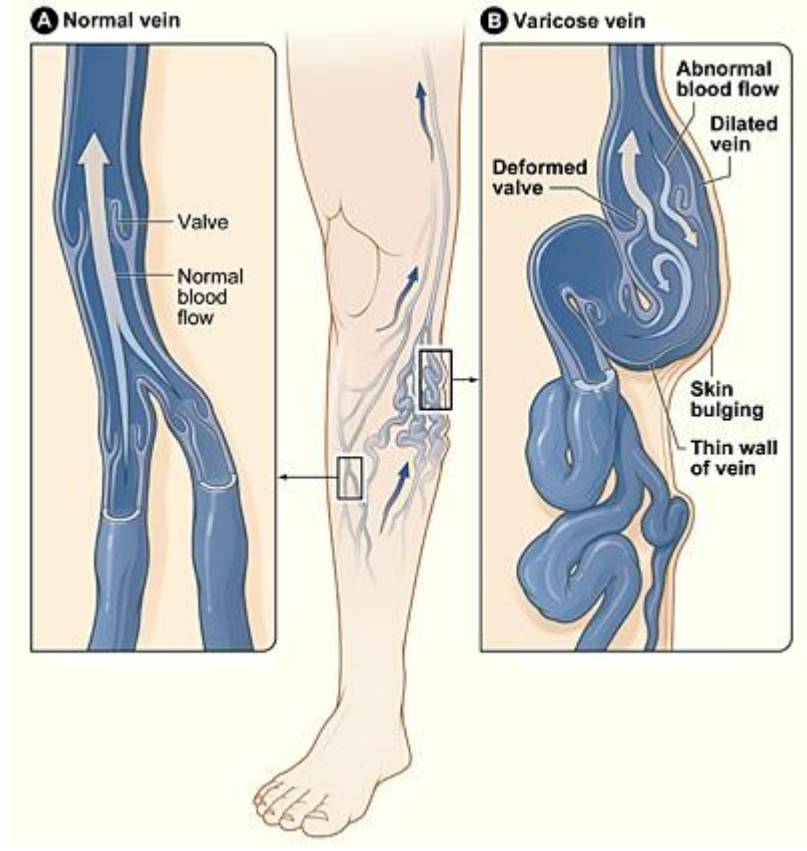
Vein Anatomy



Causes

- Thrombosis of deep veins
- Persistent elevated intra abdominal pressure
- Incompetency of valve





Symptoms

Tiredness, dull aching sensation
night cramps, tortuous veins
itching, pigmentation , eczema,
venous ulcer, disfigurement
H/o occupation

Signs: Saphena varix

Clinical test:

To see

Which system is involve?

Incompetency of perforators.

Patency of deep veins.

SCHWARTZ TEST

TORNIQUET TEST

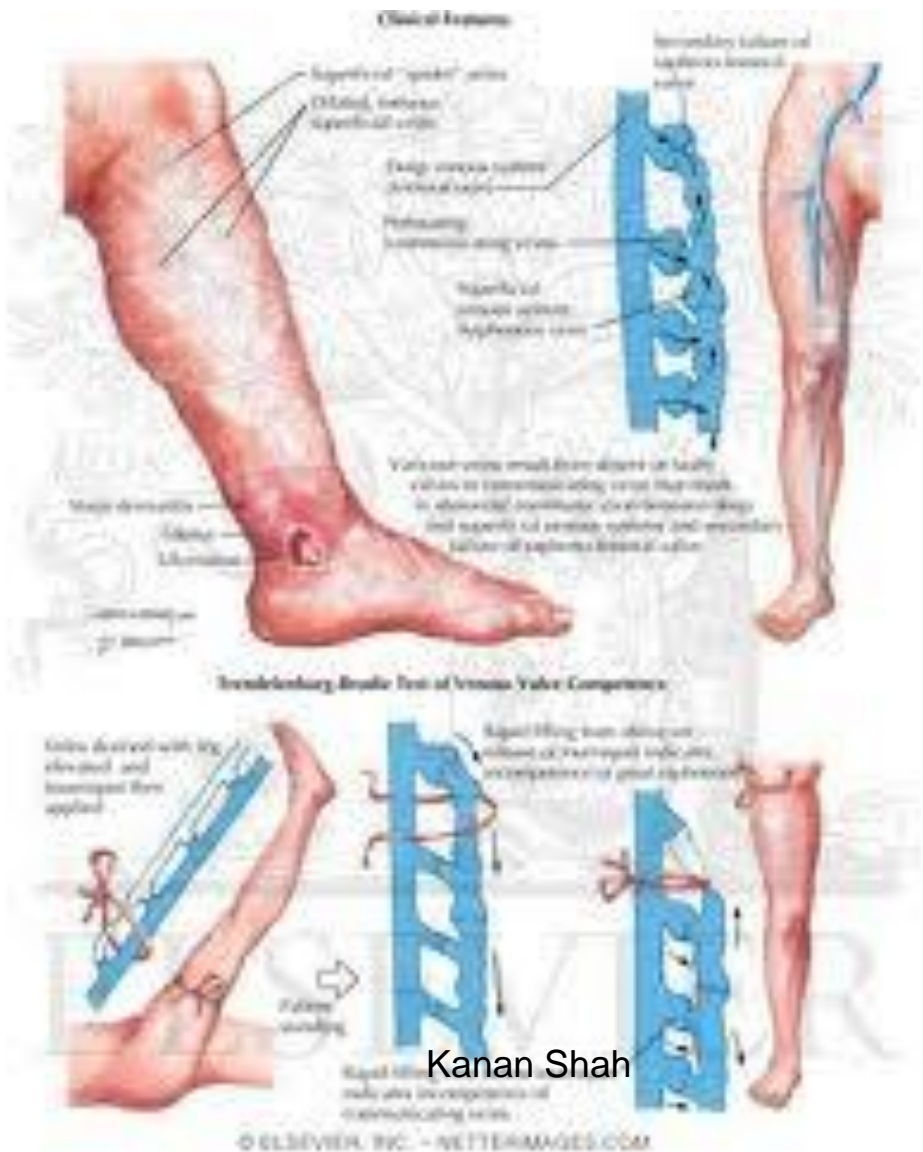
TRENDELENBURG TEST

COUGH IMPULSE TEST

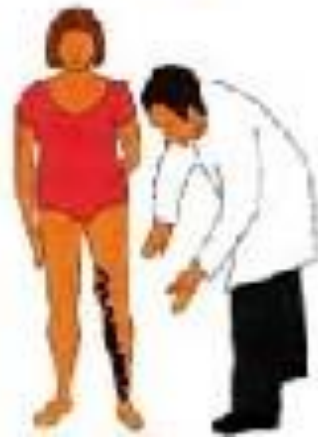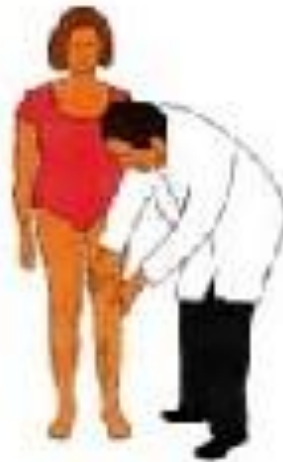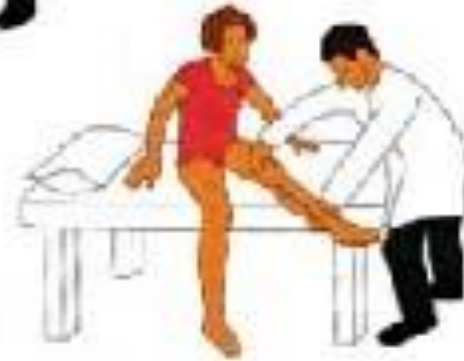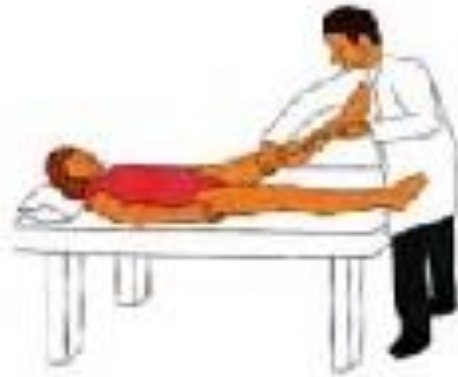PERTHE'S TEST

- **AORTIC CORONARY BY-PASS SURGERY**
- **VENESESECTION**

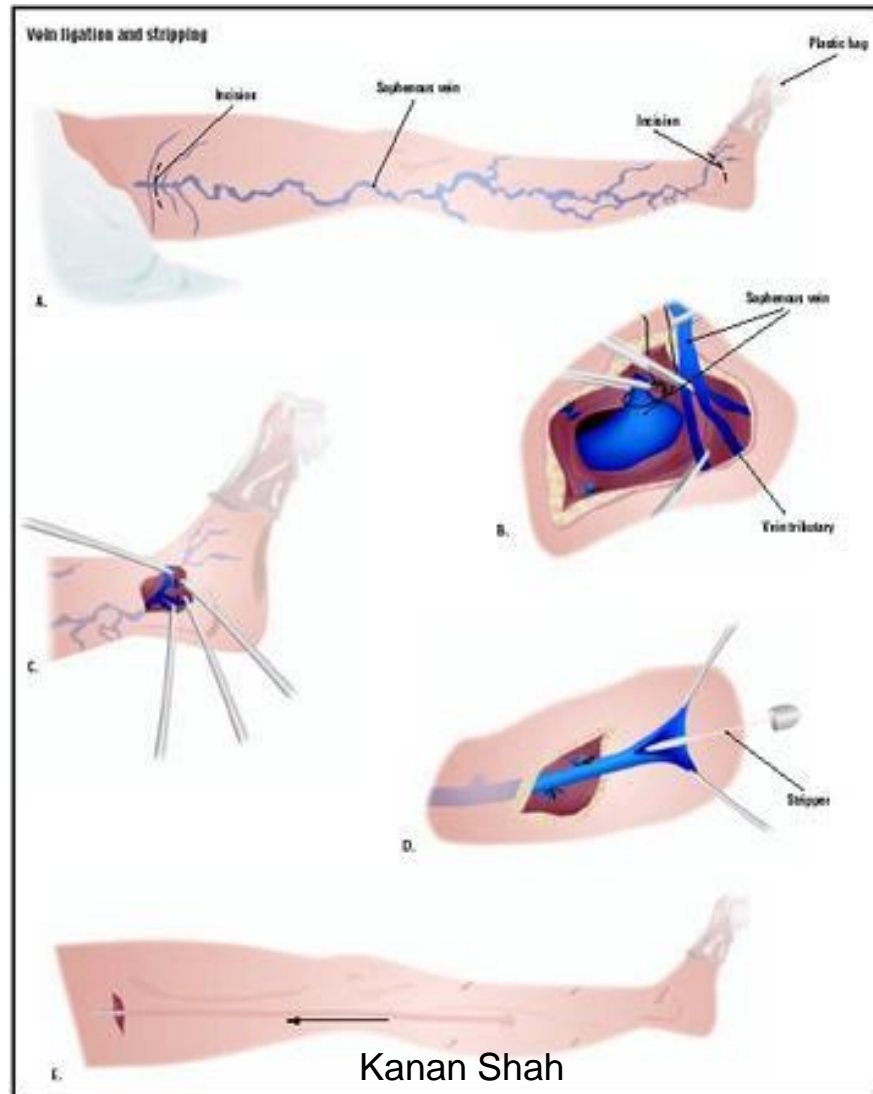
TORNIQUET TEST



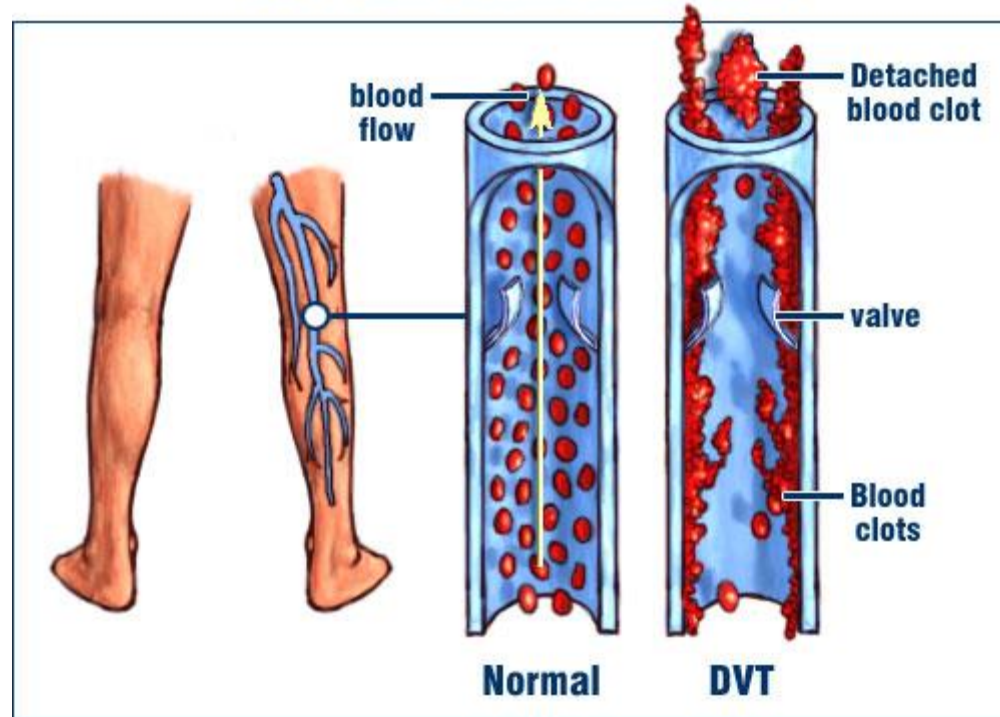
TRENDELENBURG TEST



VENESECTION



Deep Vein Thrombosis (DVT)



Pulmonary embolism

Kanan Shah

Aknowledgements

- Human Anatomy by BD Chaurasia
- Gray's Anatomy
- Essentials of Human Antomy: Upper Limb and Lower Limb by Asimkumar Dutta