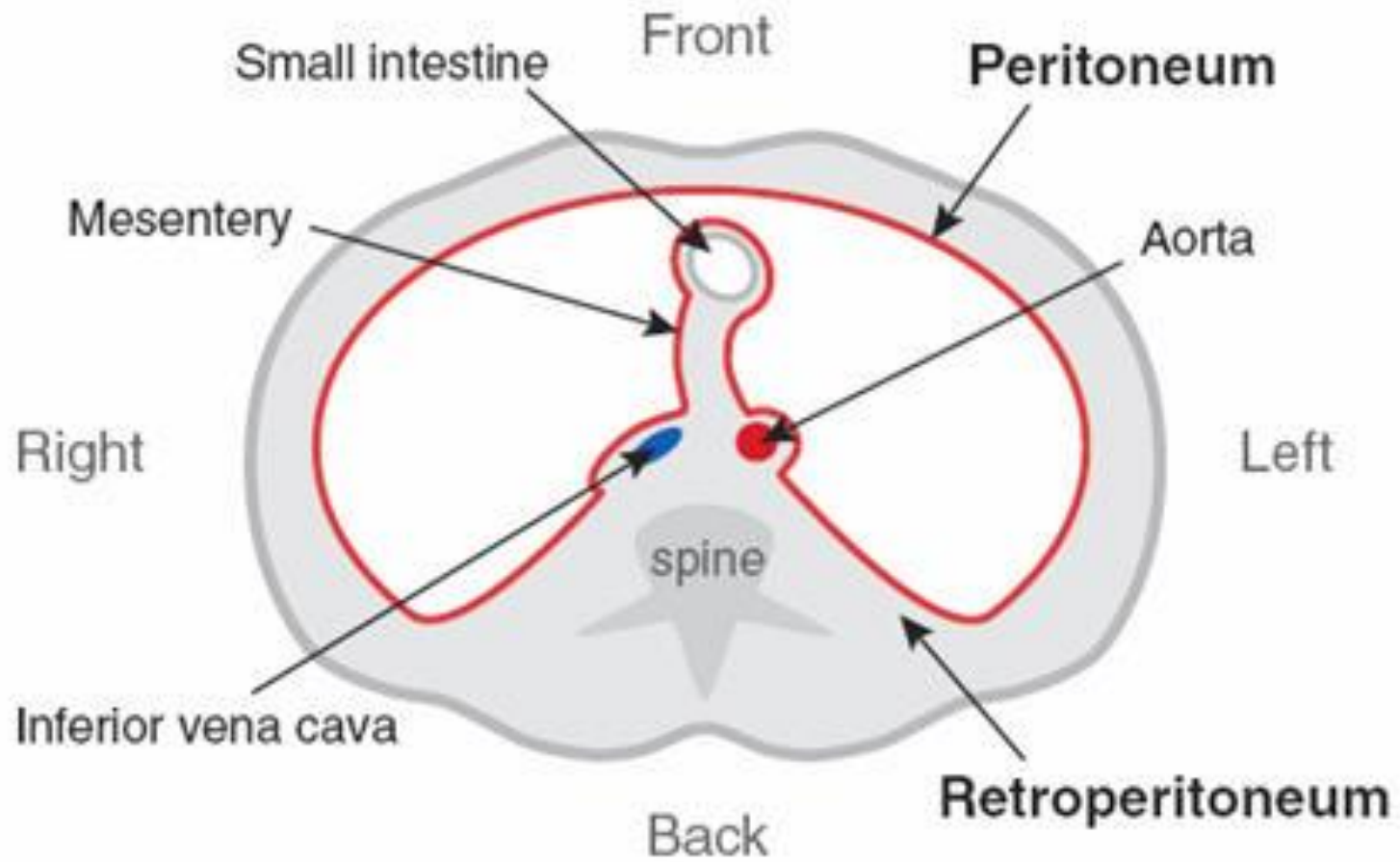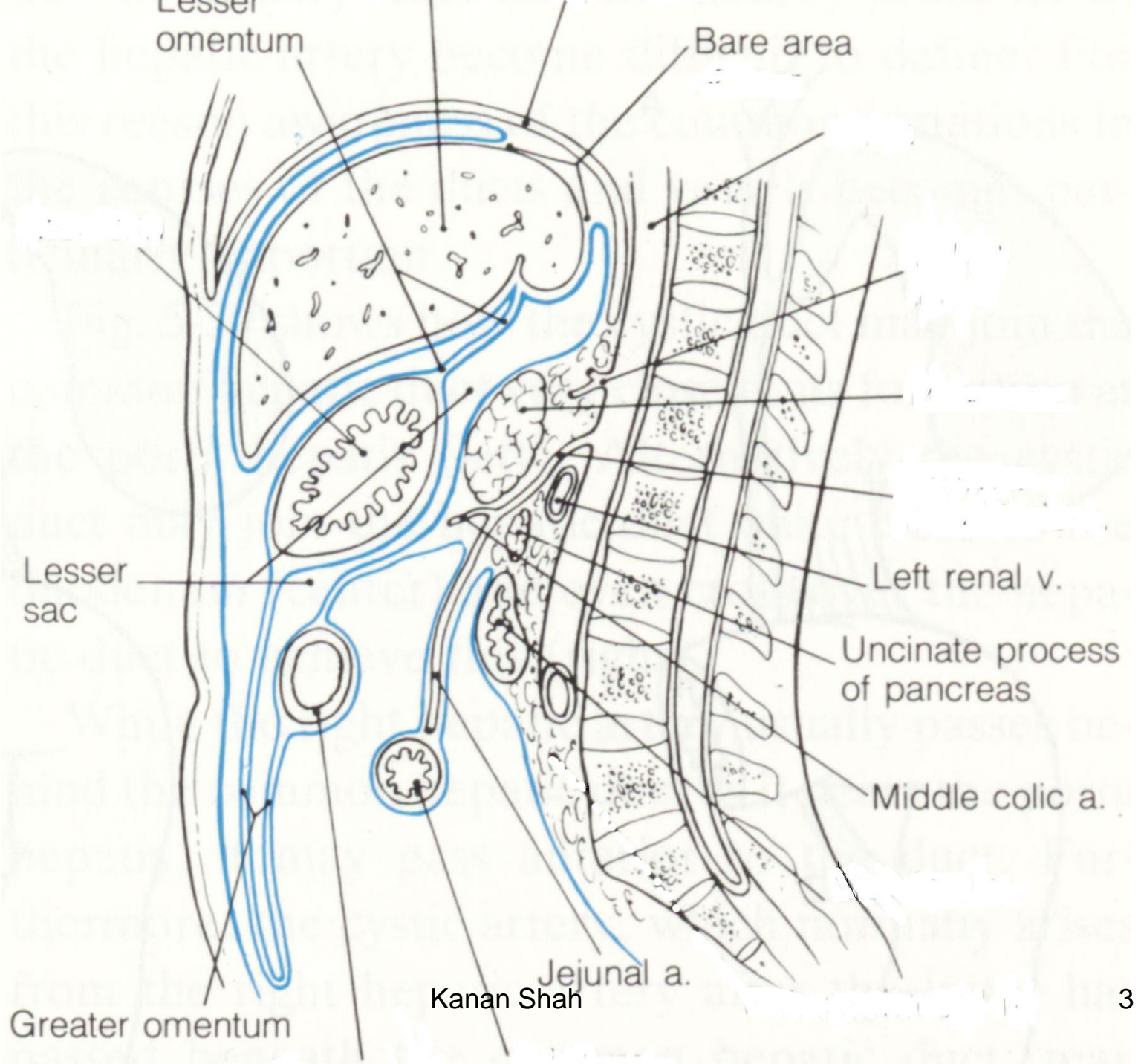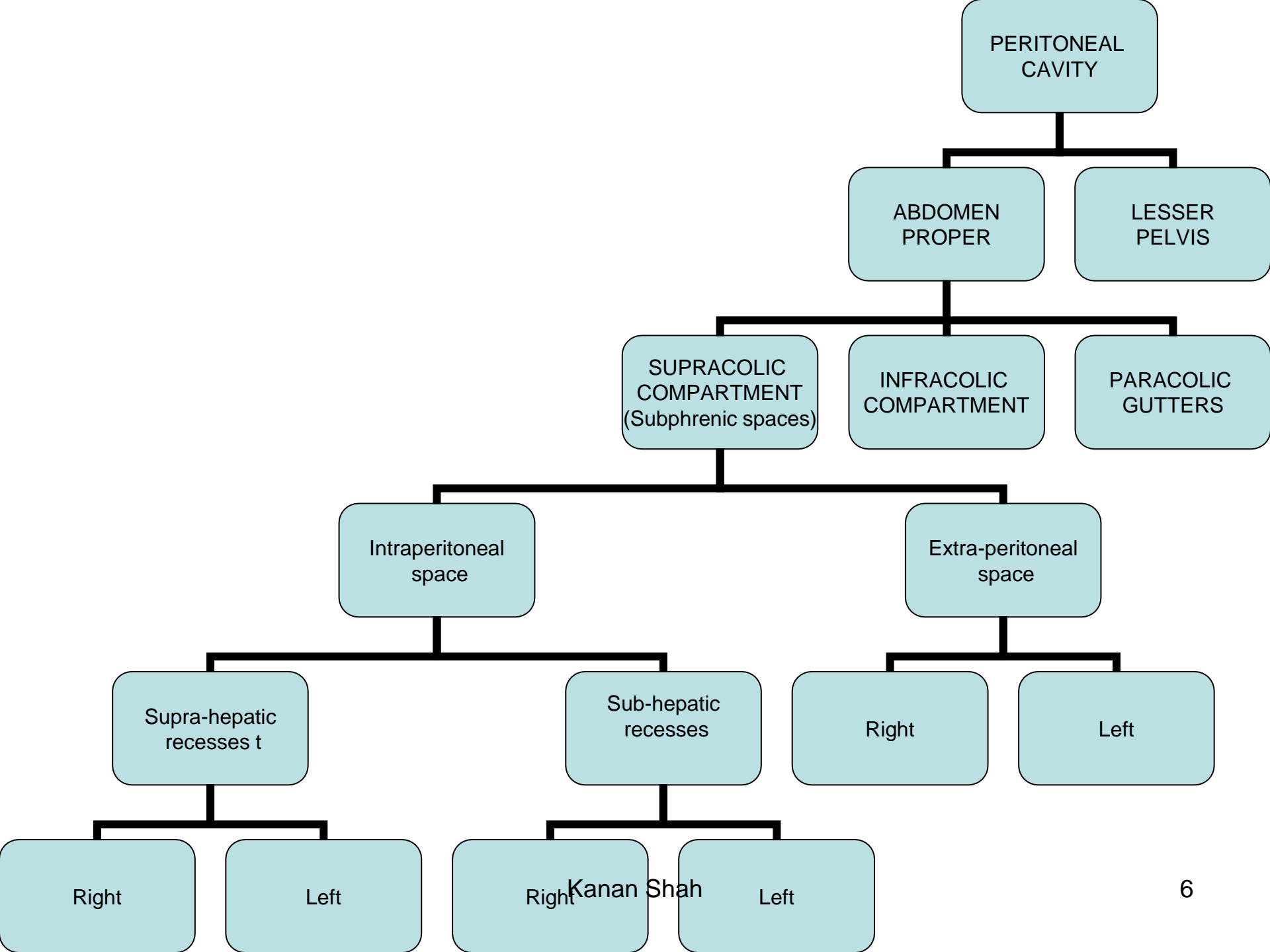


Kanan Shah

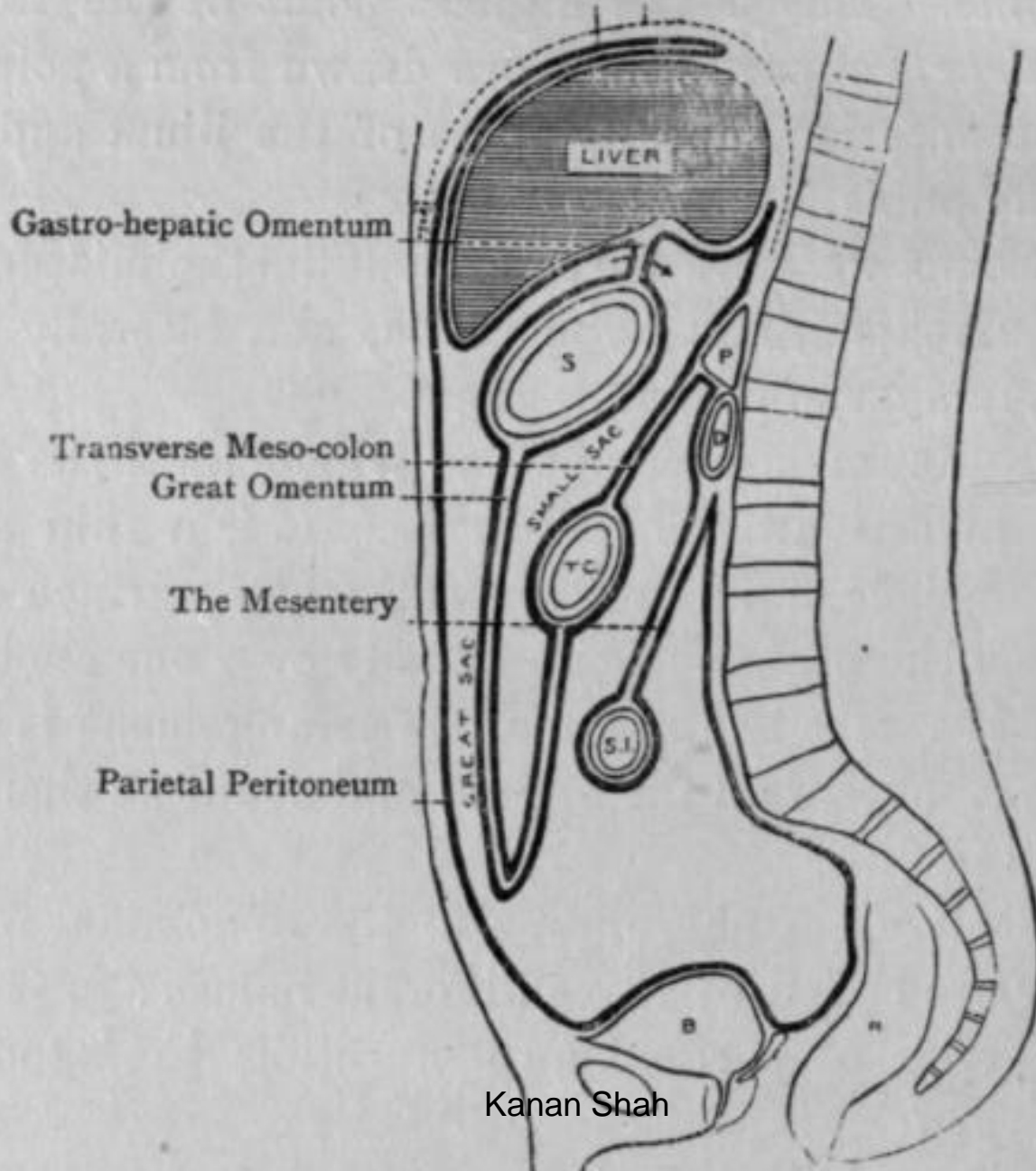
PERITONEAL RECESSES

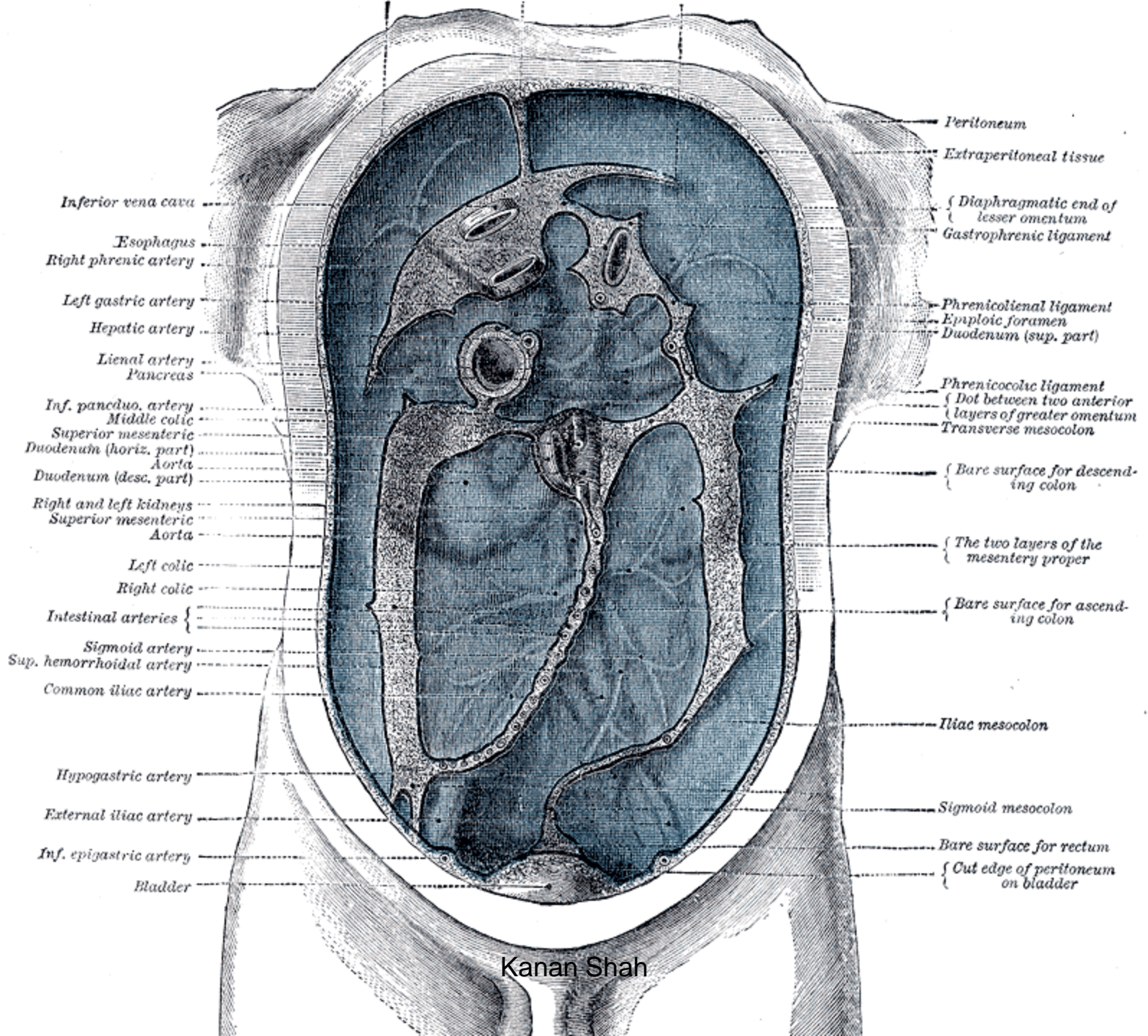


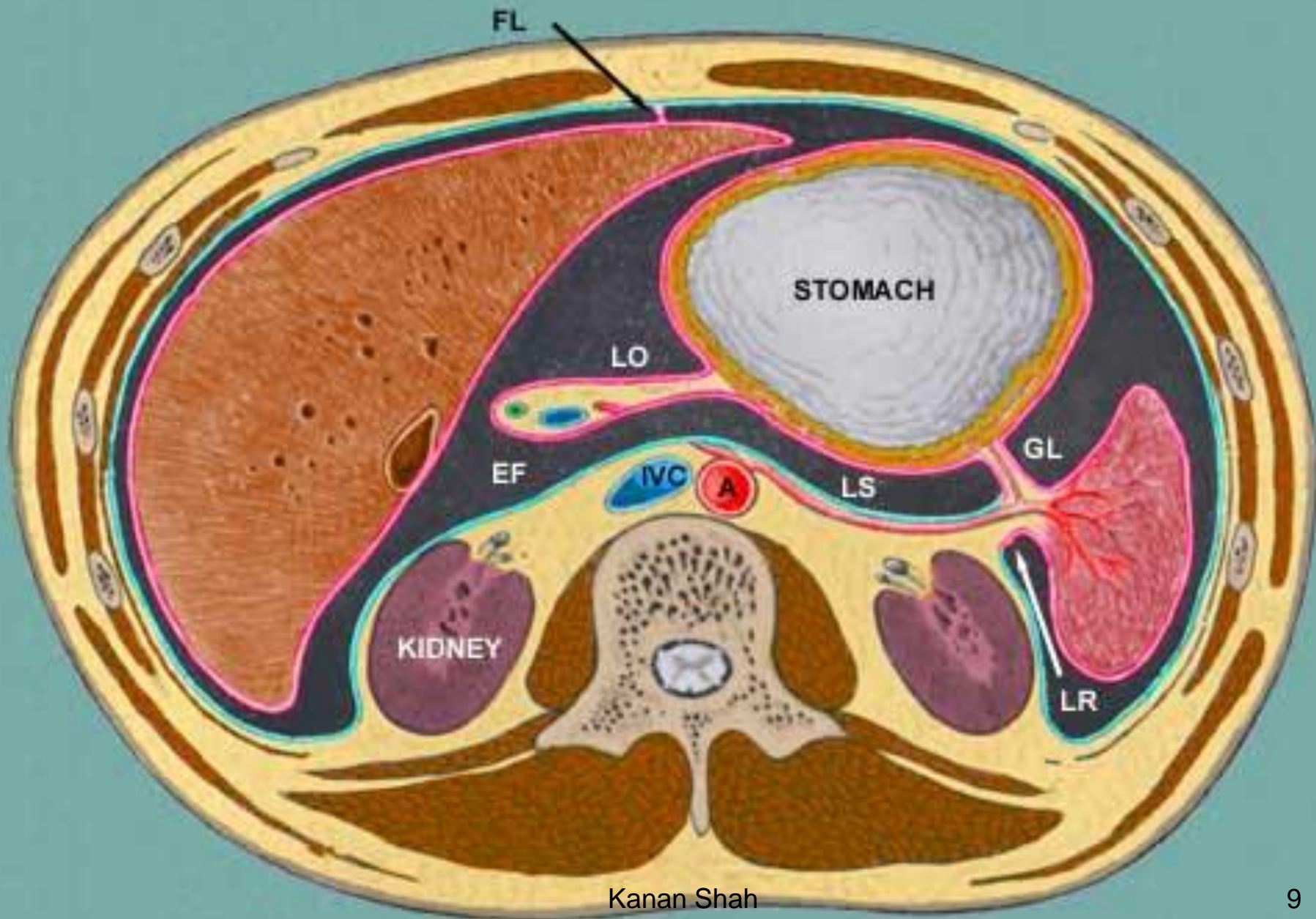
Kanan Shah



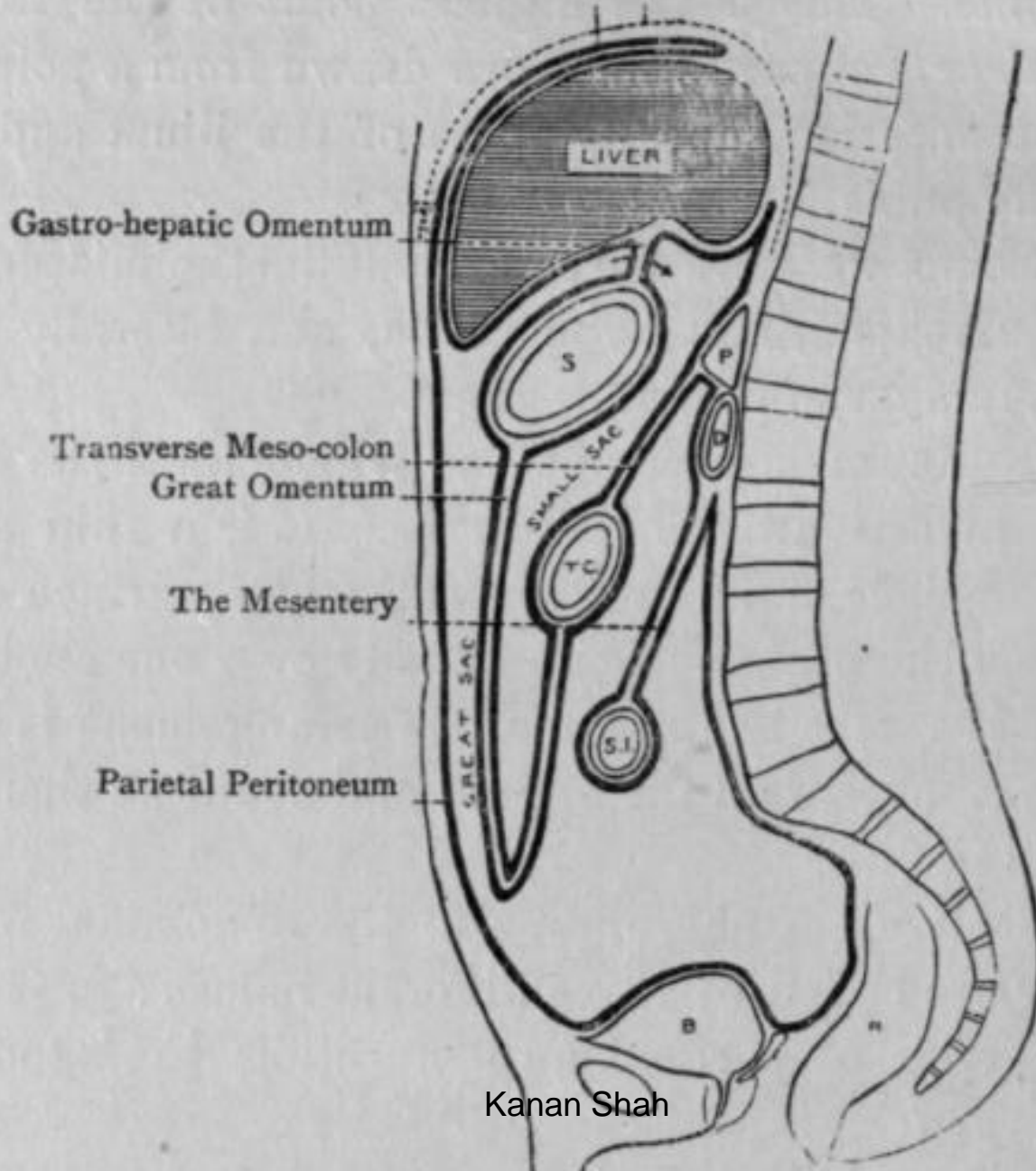
Parietal Peritoneum Outline of Diaphragm

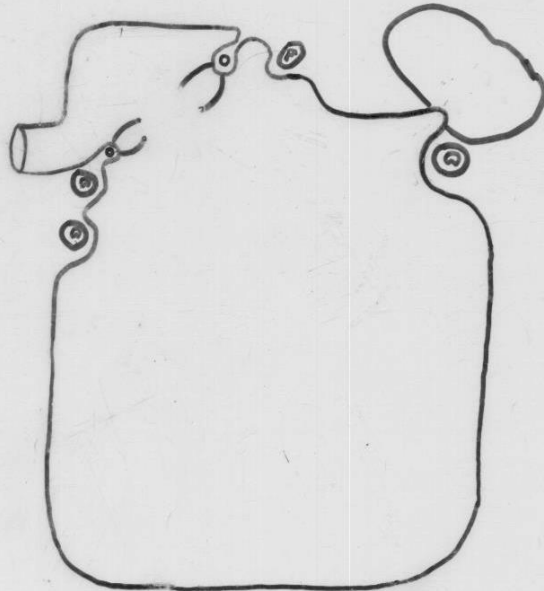
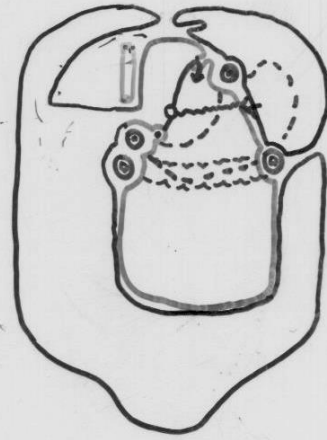
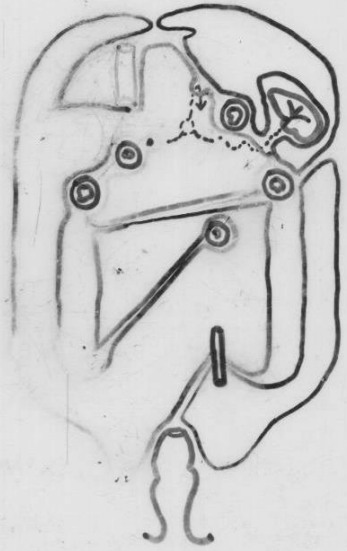






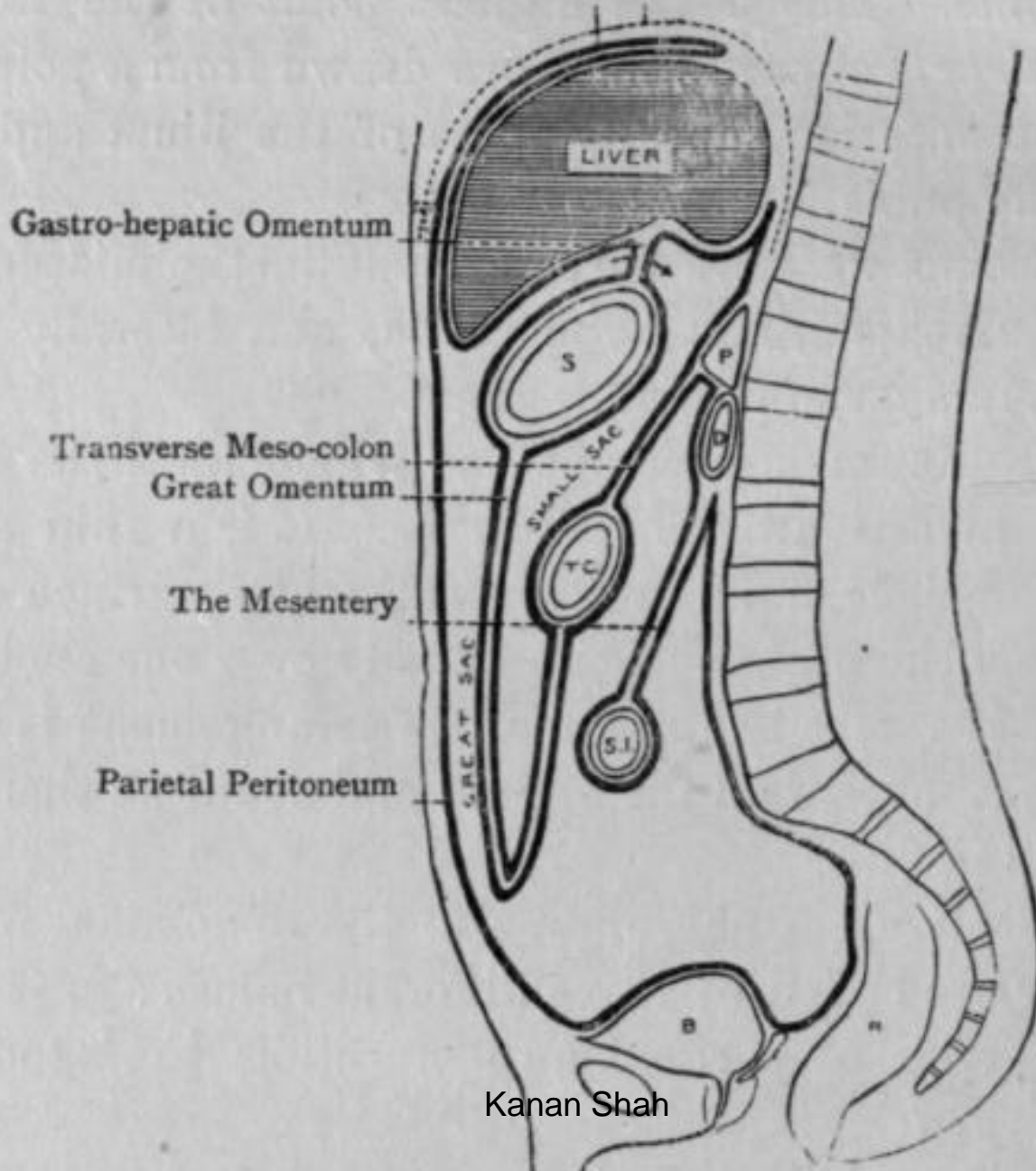
Parietal Peritoneum Outline of Diaphragm

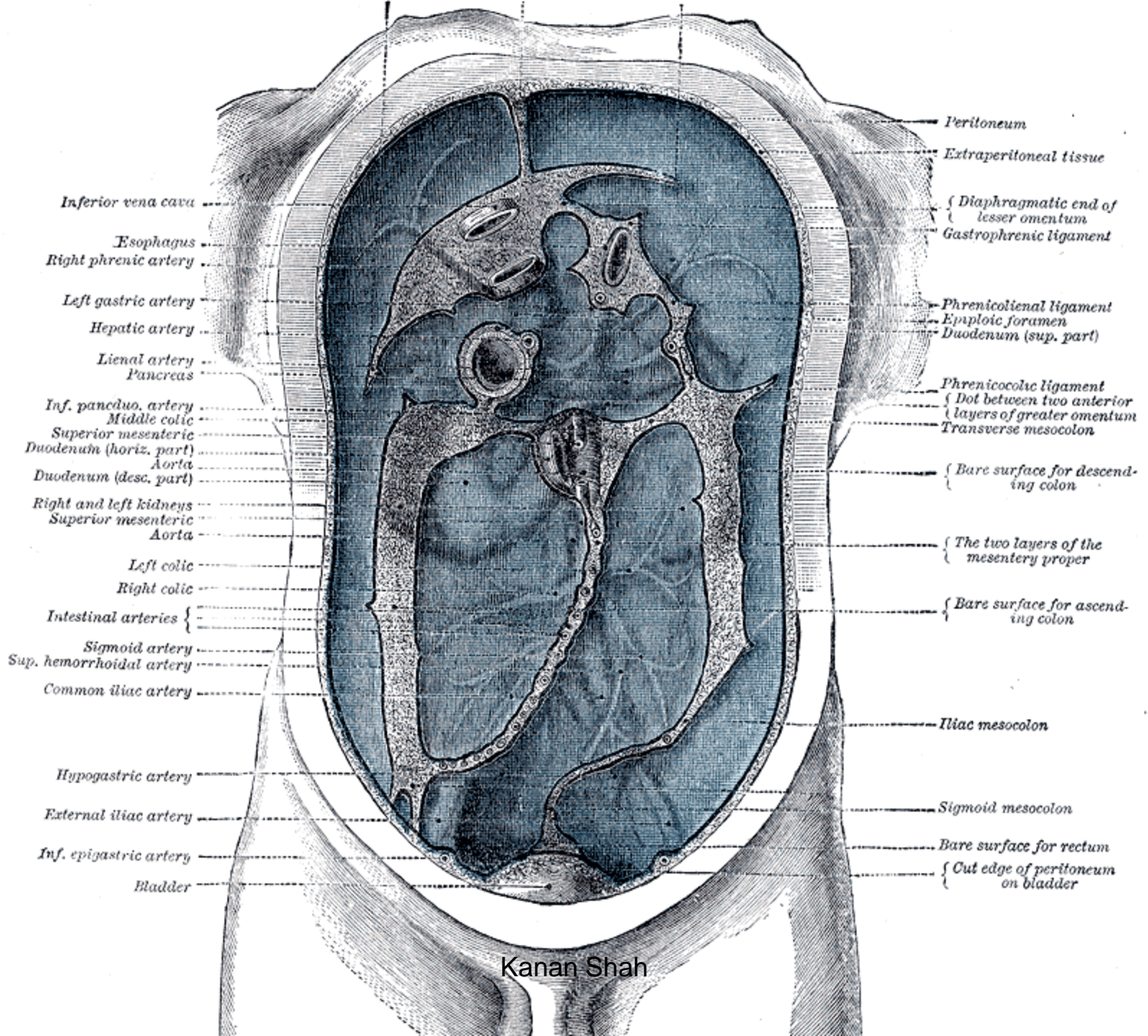


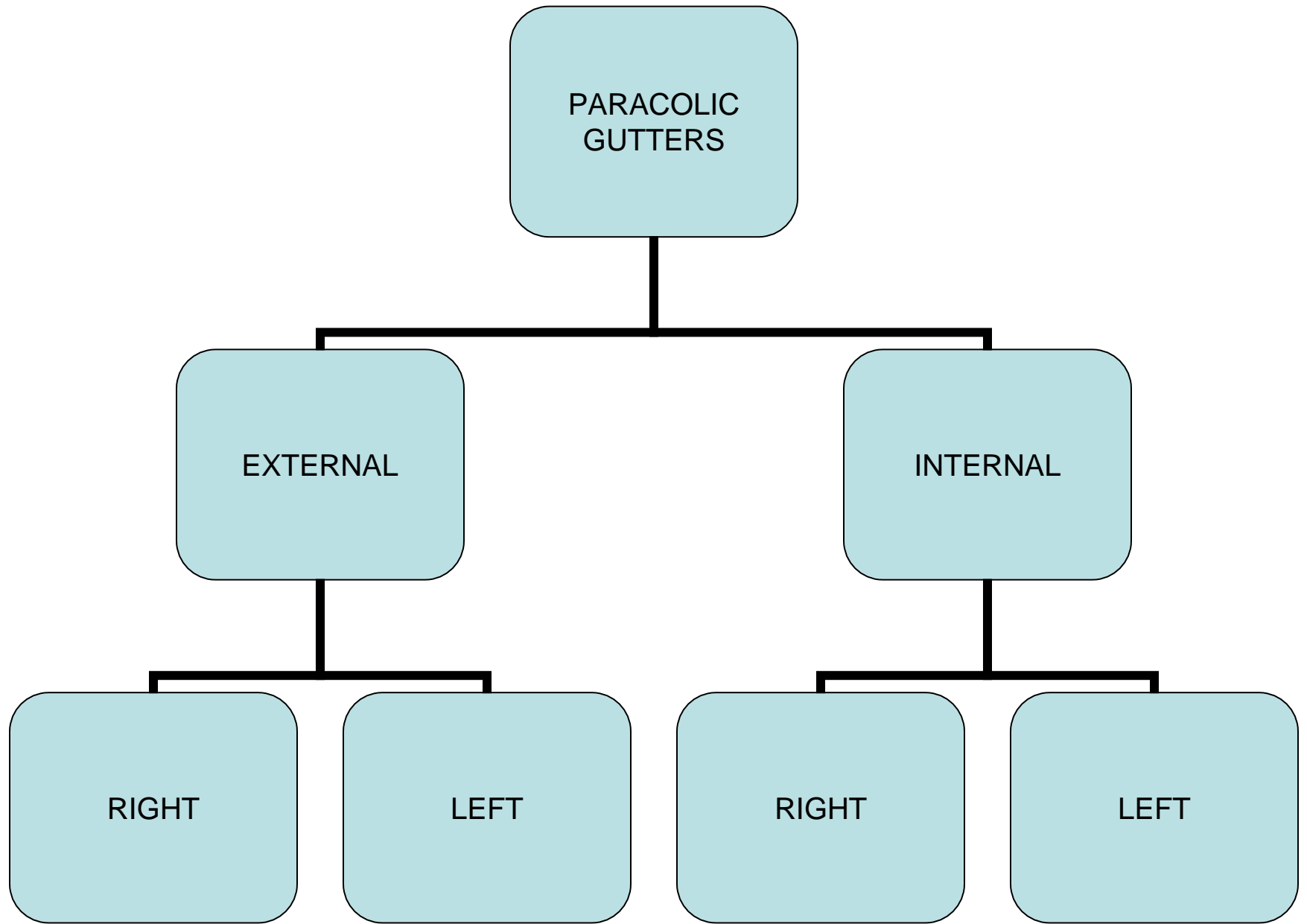


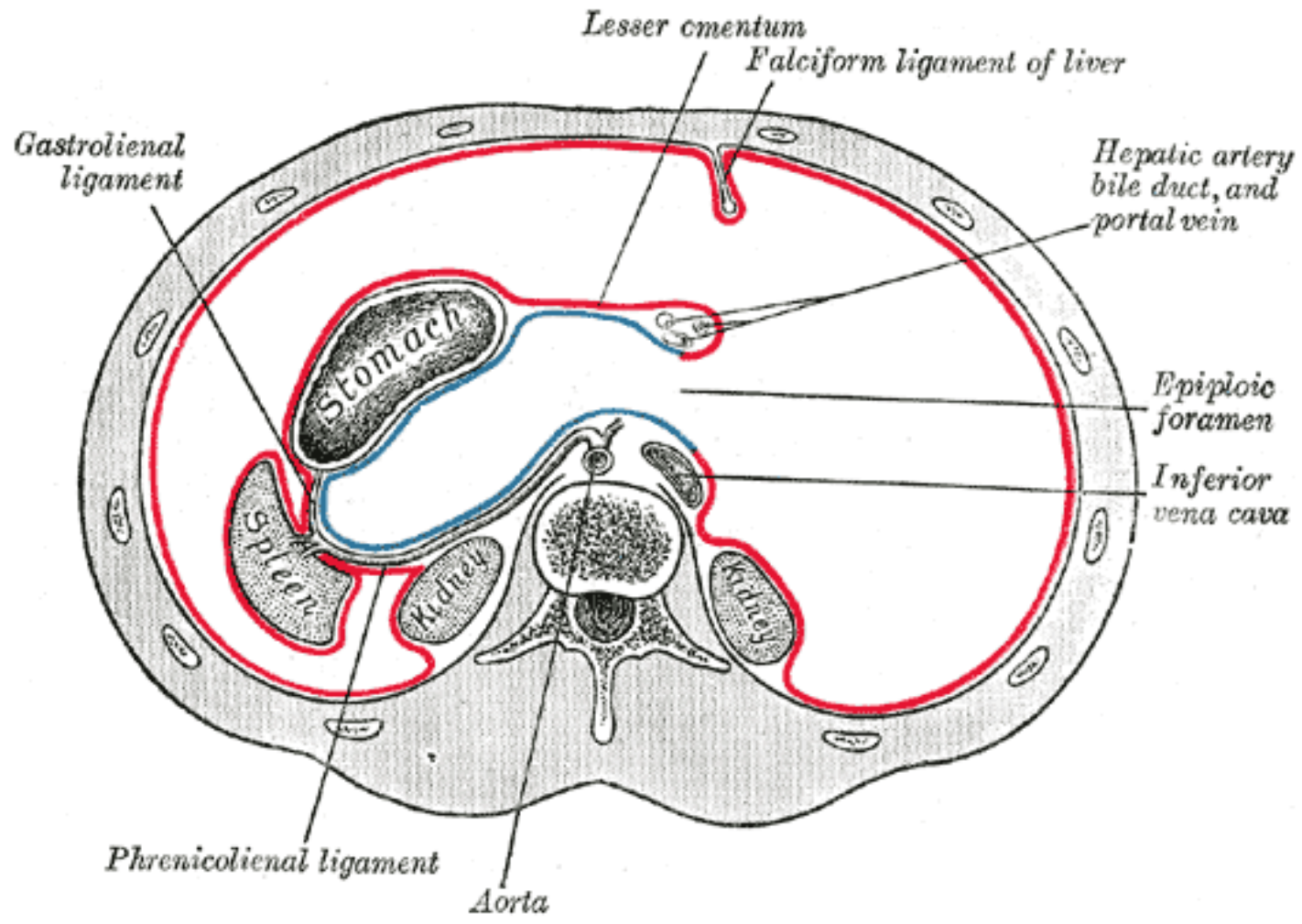
Kanan Shah

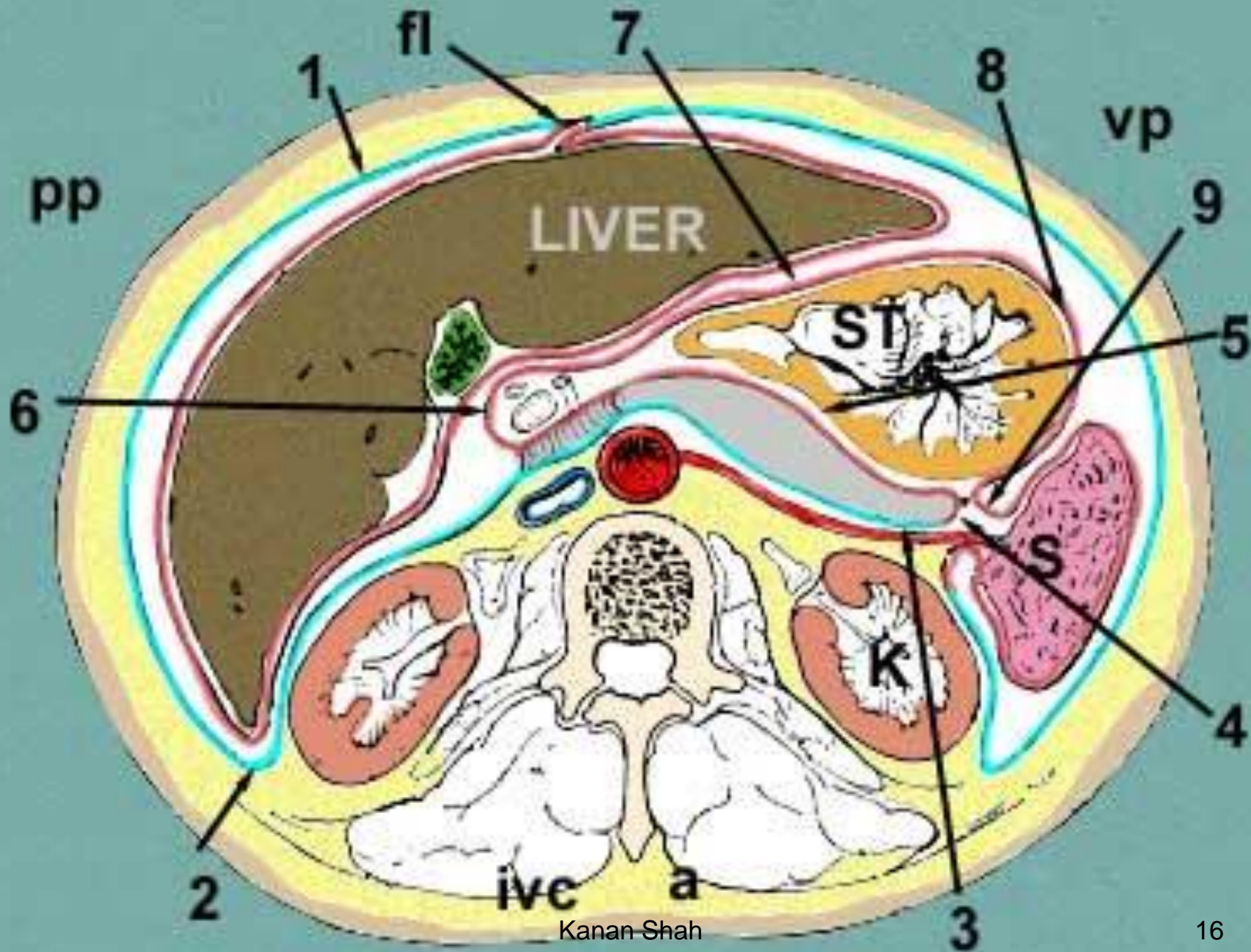
Parietal Peritoneum Outline of Diaphragm

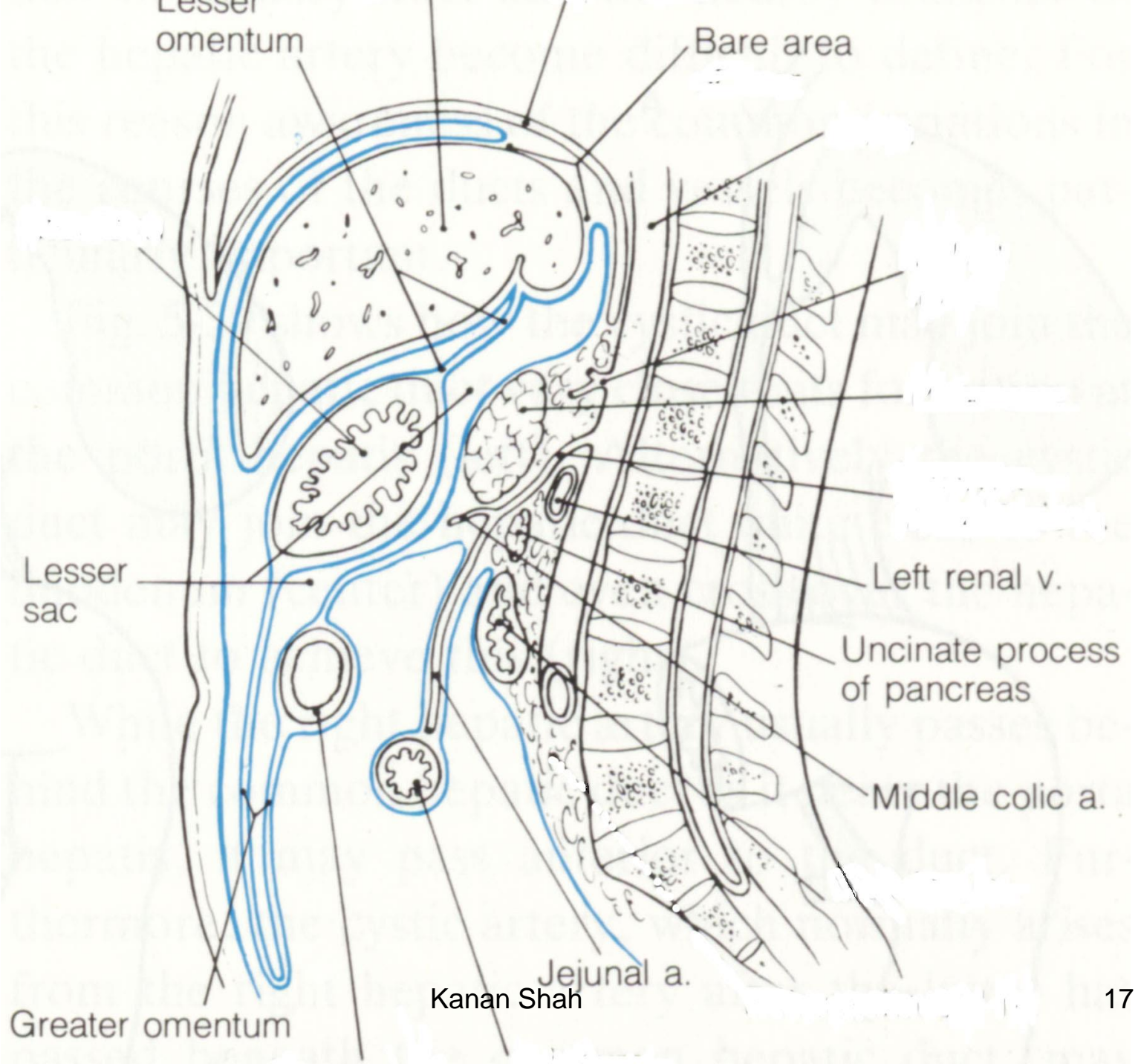


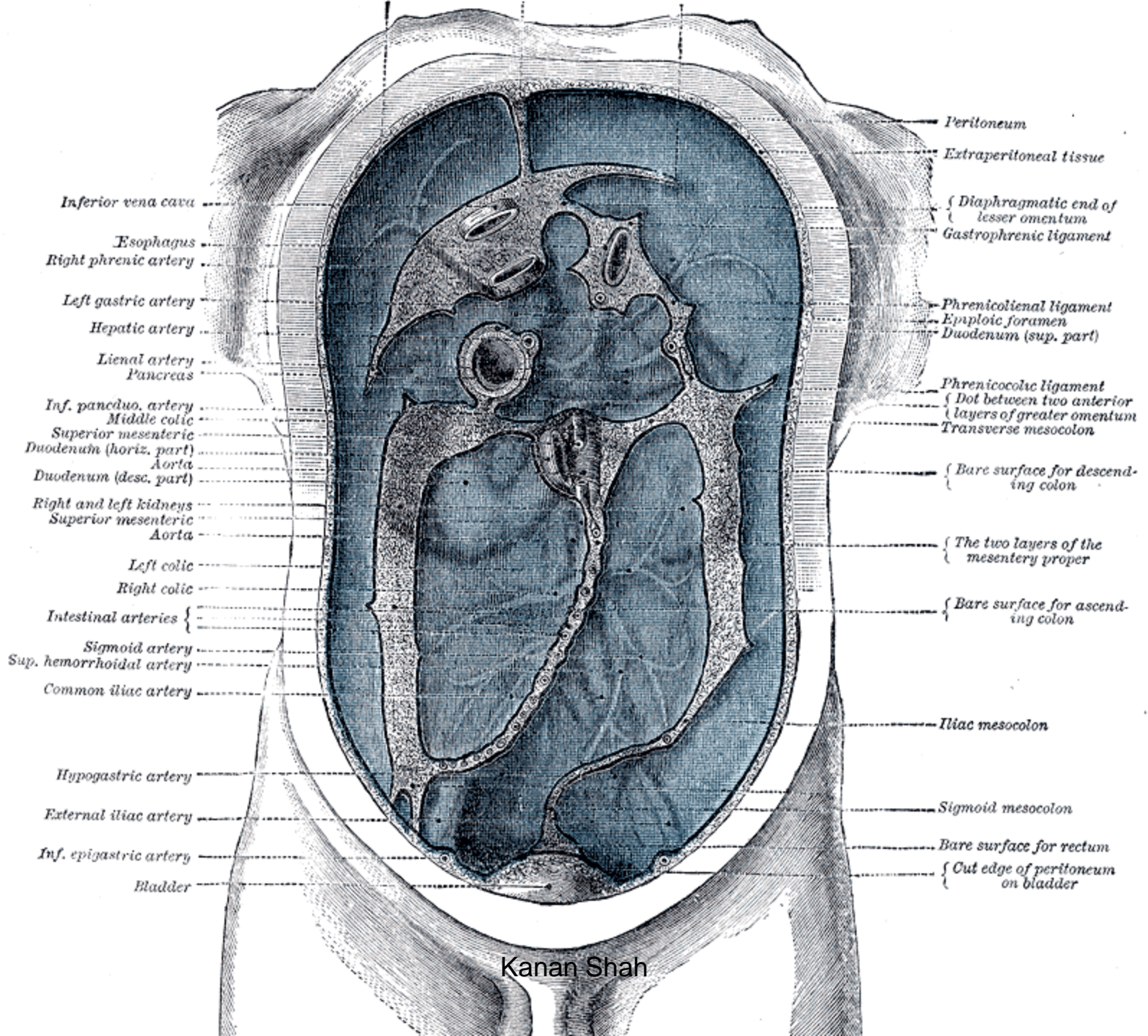


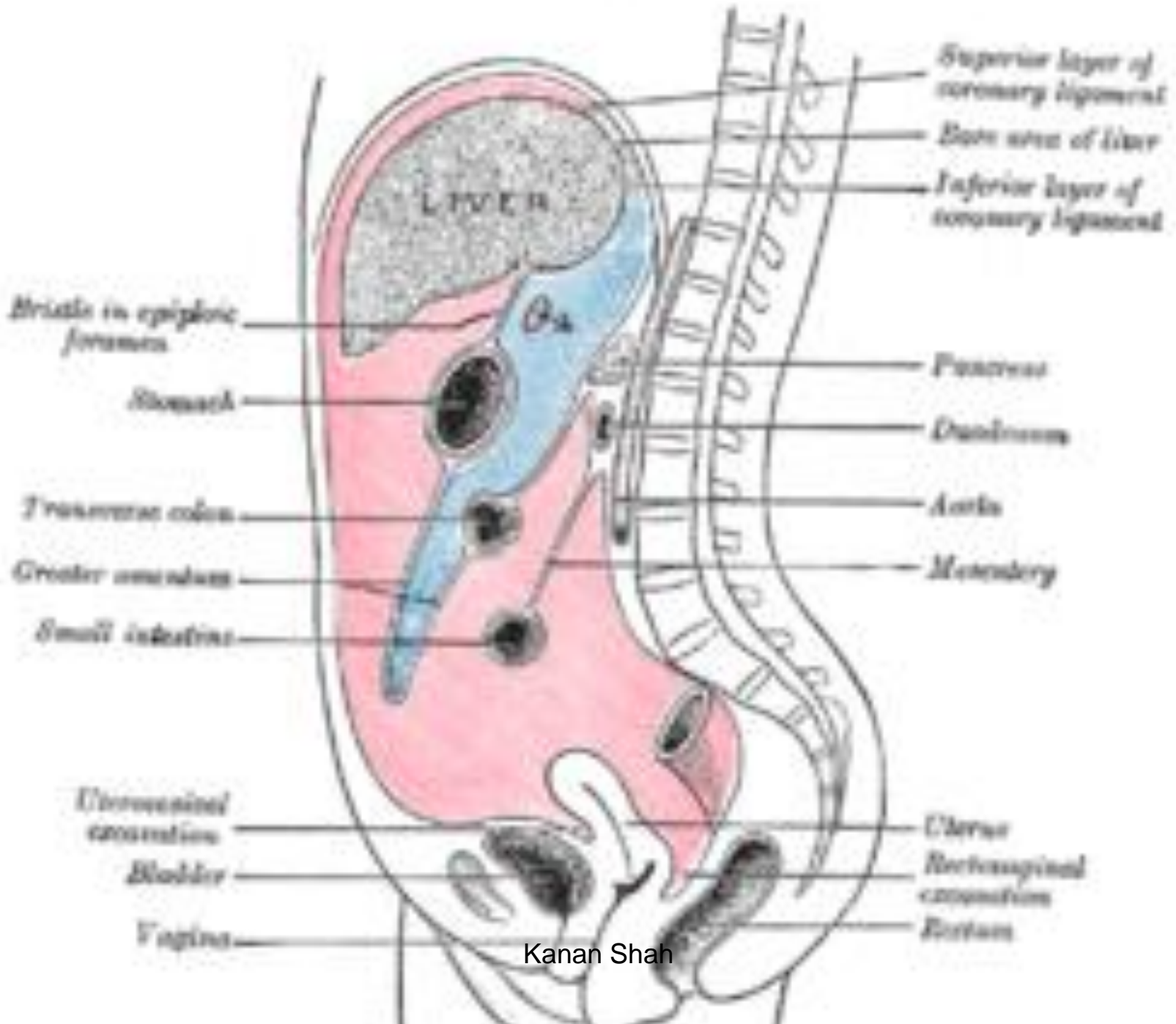




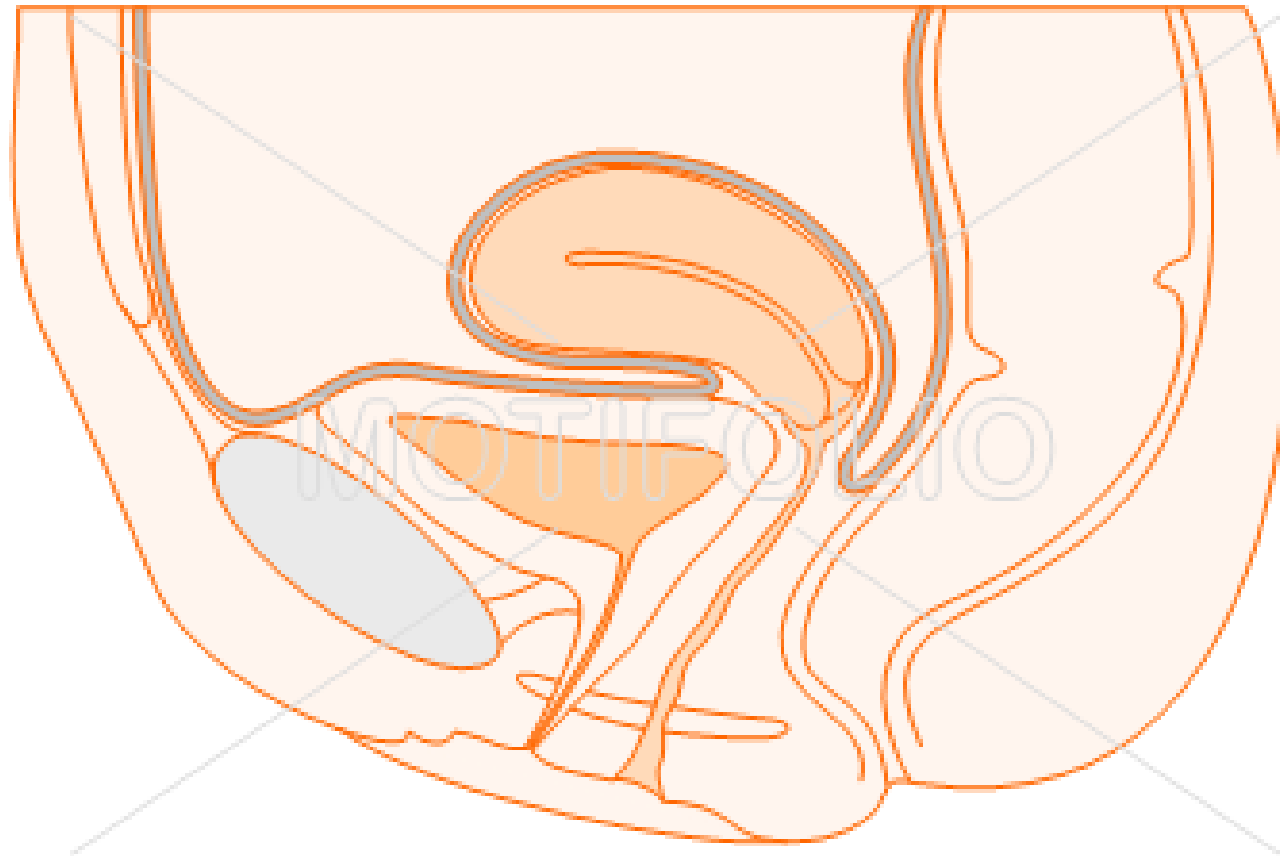




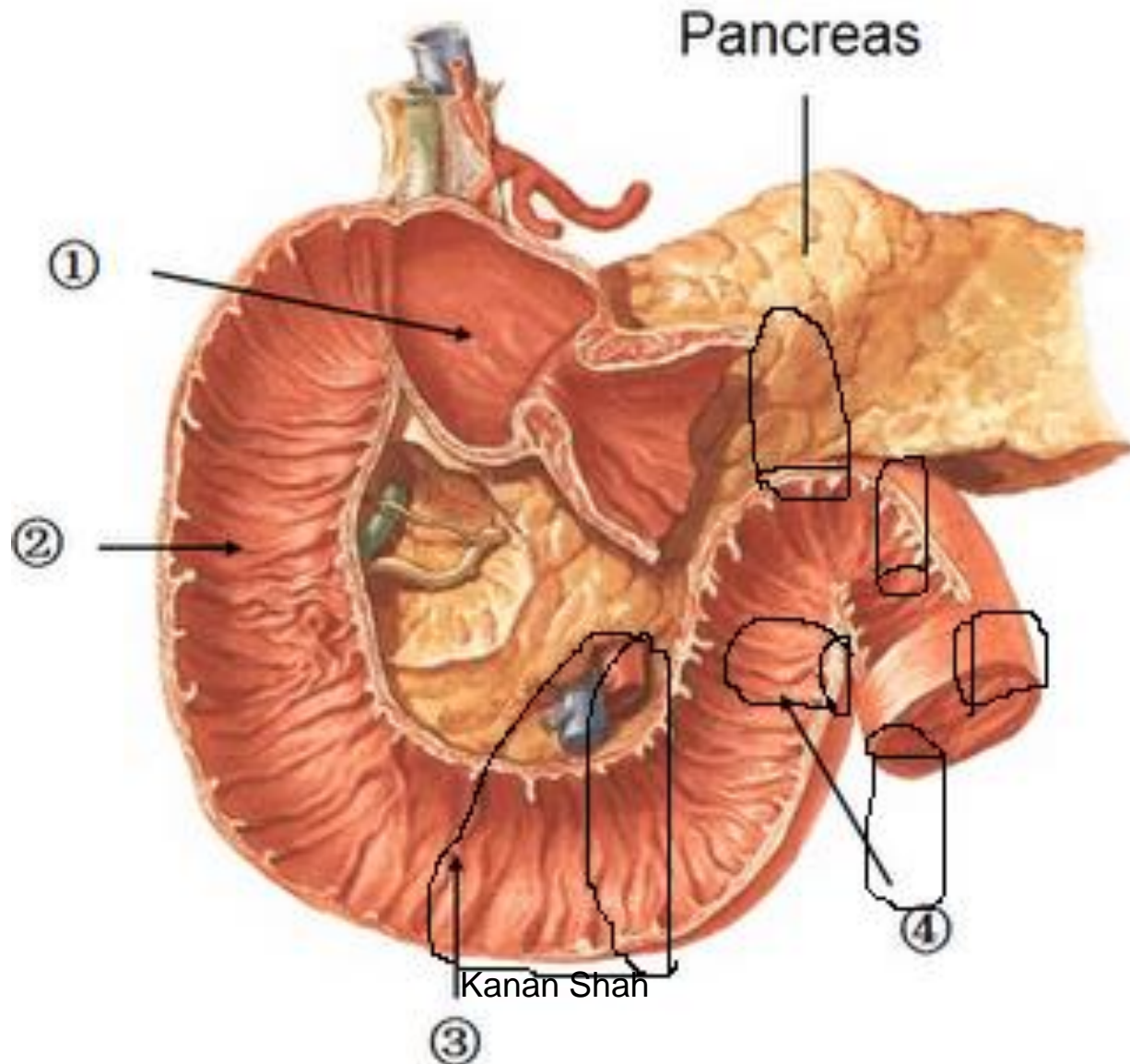




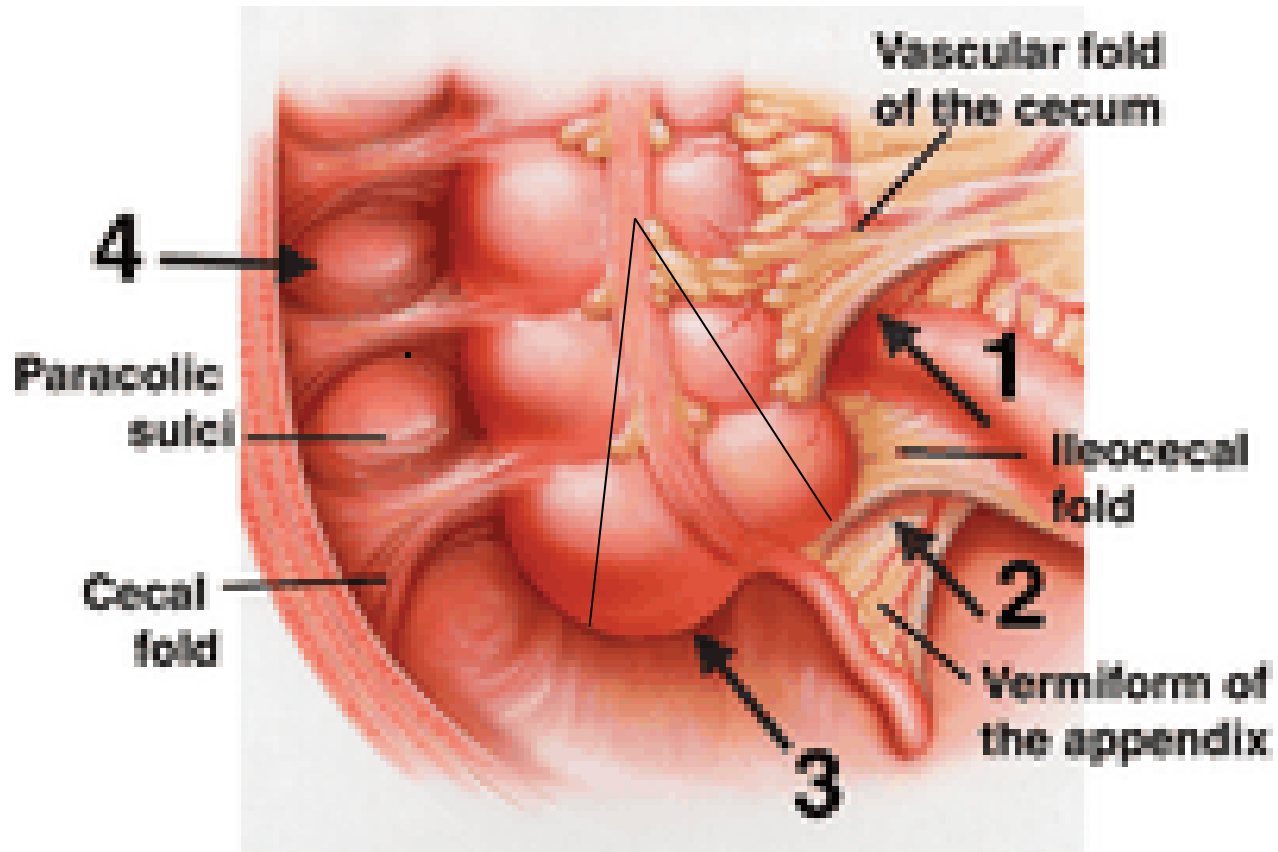
Peritoneum covering female pelvic organs



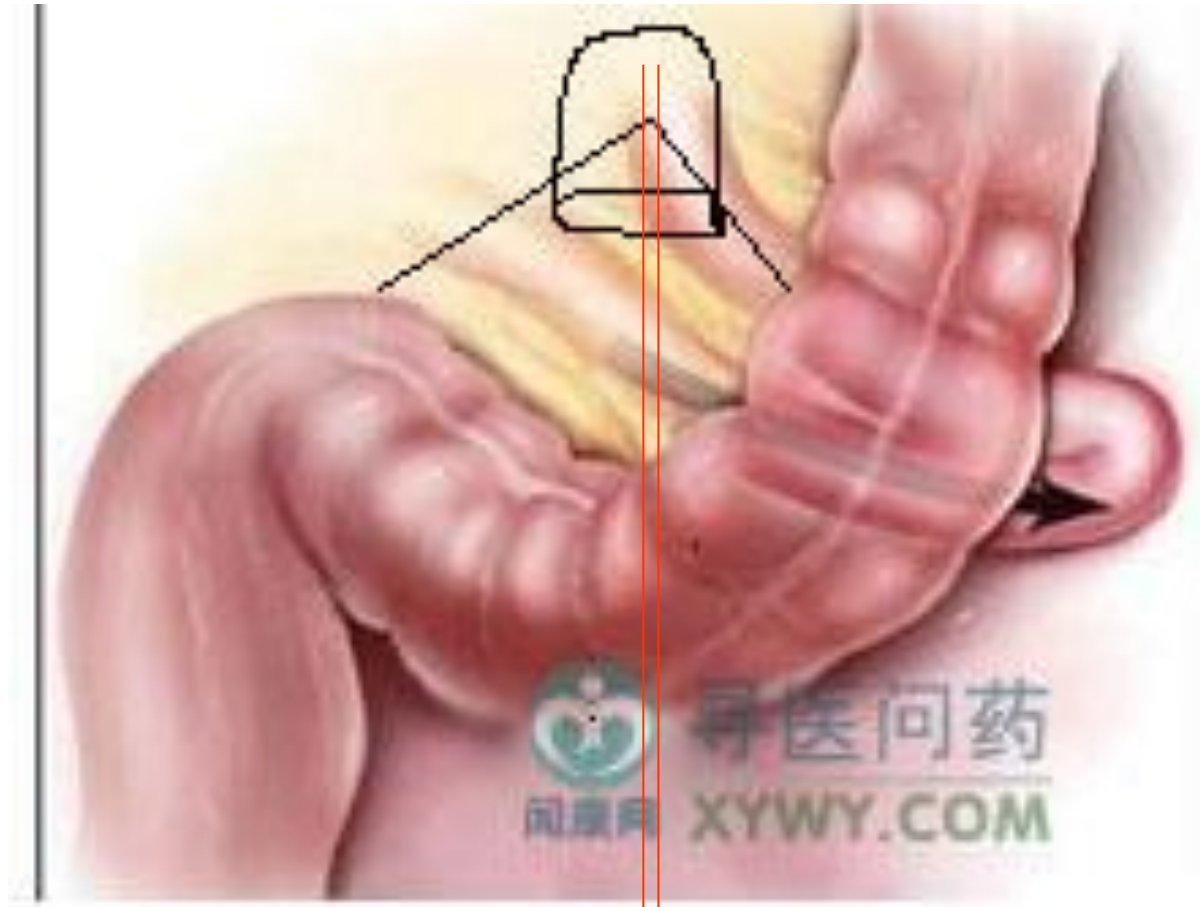DUODENAL RECESSES



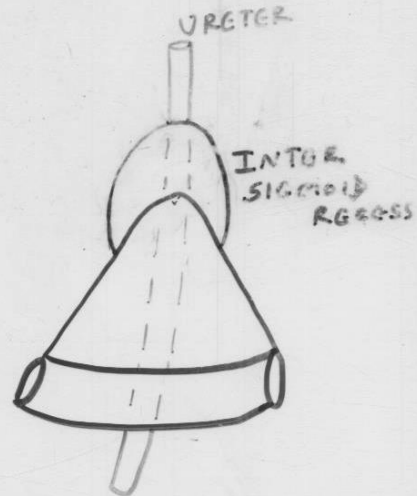
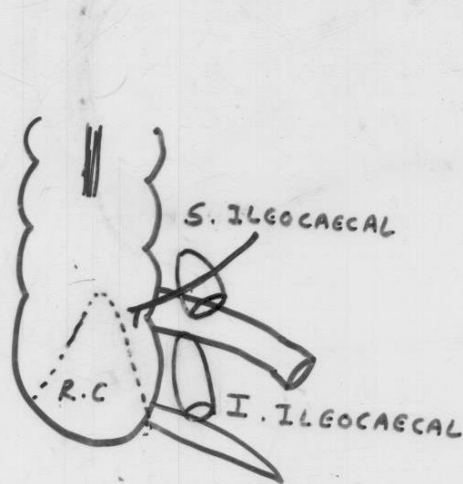
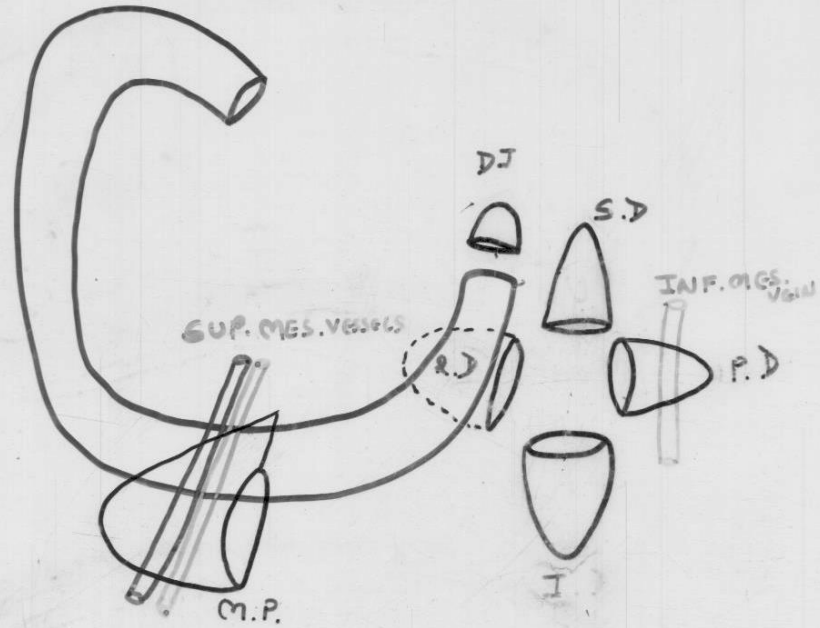
CAECAI RECESSES



INTERSIGMOID RECESS



PERITONEAL RECESSES



Aknowledgements

- Human Anatomy by BD Chaurasia
- Gray's Anatomy
- Essentials of Human Antomy: Thorax and Abdomen by Asimkumar Dutta