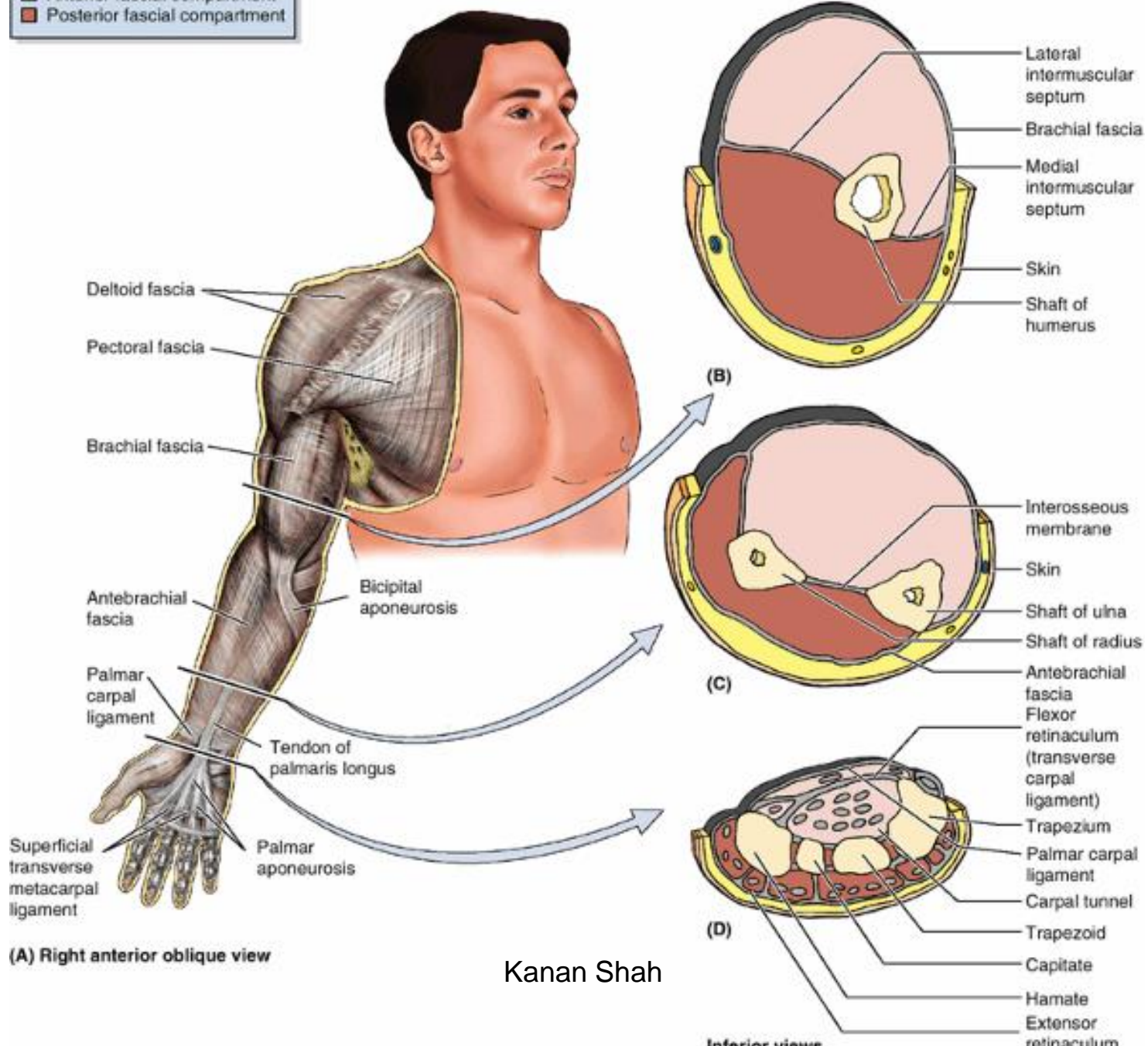


FASCIAL SPACES IN HAND

ARRANGEMENT OF FASCIA
AND THE FASCIAL SEPTA IN
HAND FORMS MANY SPACES

Key

- Anterior fascial compartment
- Posterior fascial compartment



(A) Right anterior oblique view

Kanan Shah

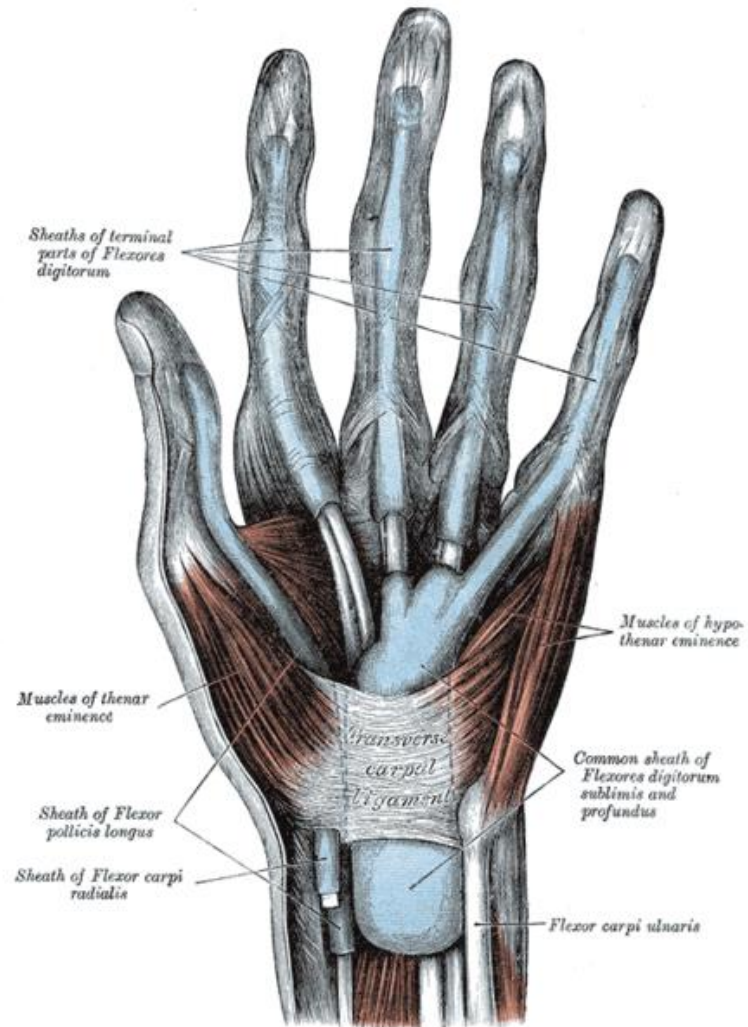
PALMER SPACES

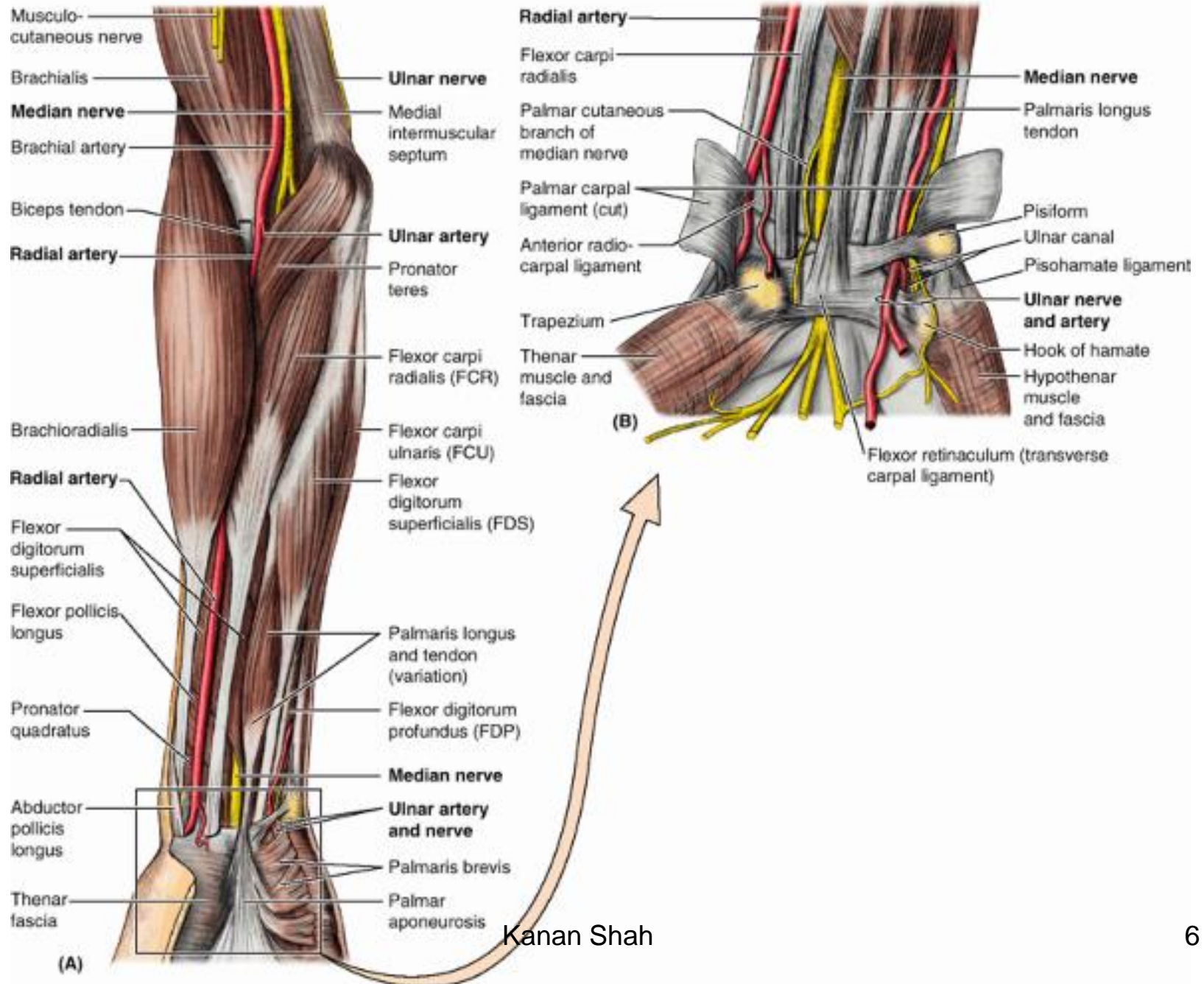
- PULP SPACES
- THE DIGITAL SYNOVIAL SHEATH
- ULNAR BURSA
- RADIAL BURSA
- MID PALMER SPACE
- THENAR SPACE

DORSAL SPACES

- Dorsal subcutaneous space
- Dorsal subaponeurotic space

SPACE OF PARONA



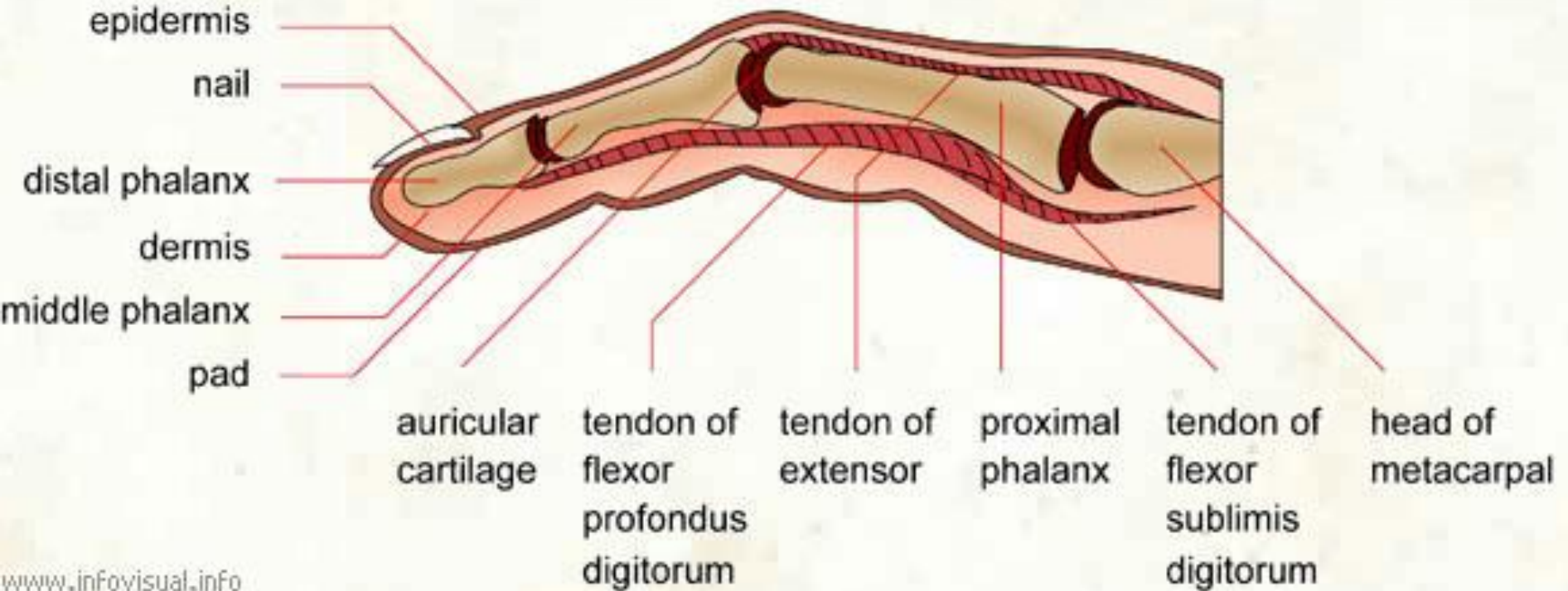


PALMER SPACES

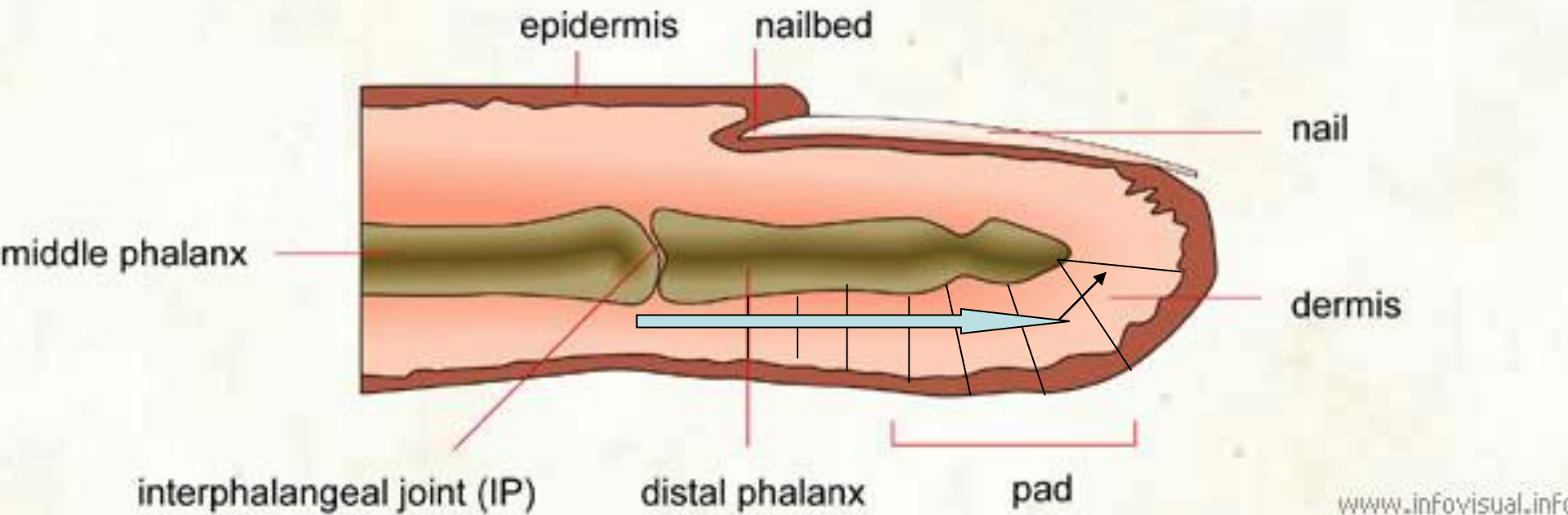
- PULP SPACES
- THE DIGITAL SYNOVIAL SHEATH
- ULNAR BURSA
- RADIAL BURSA
- MID PALMER SPACE
- THENAR SPACE

PULP SPACE

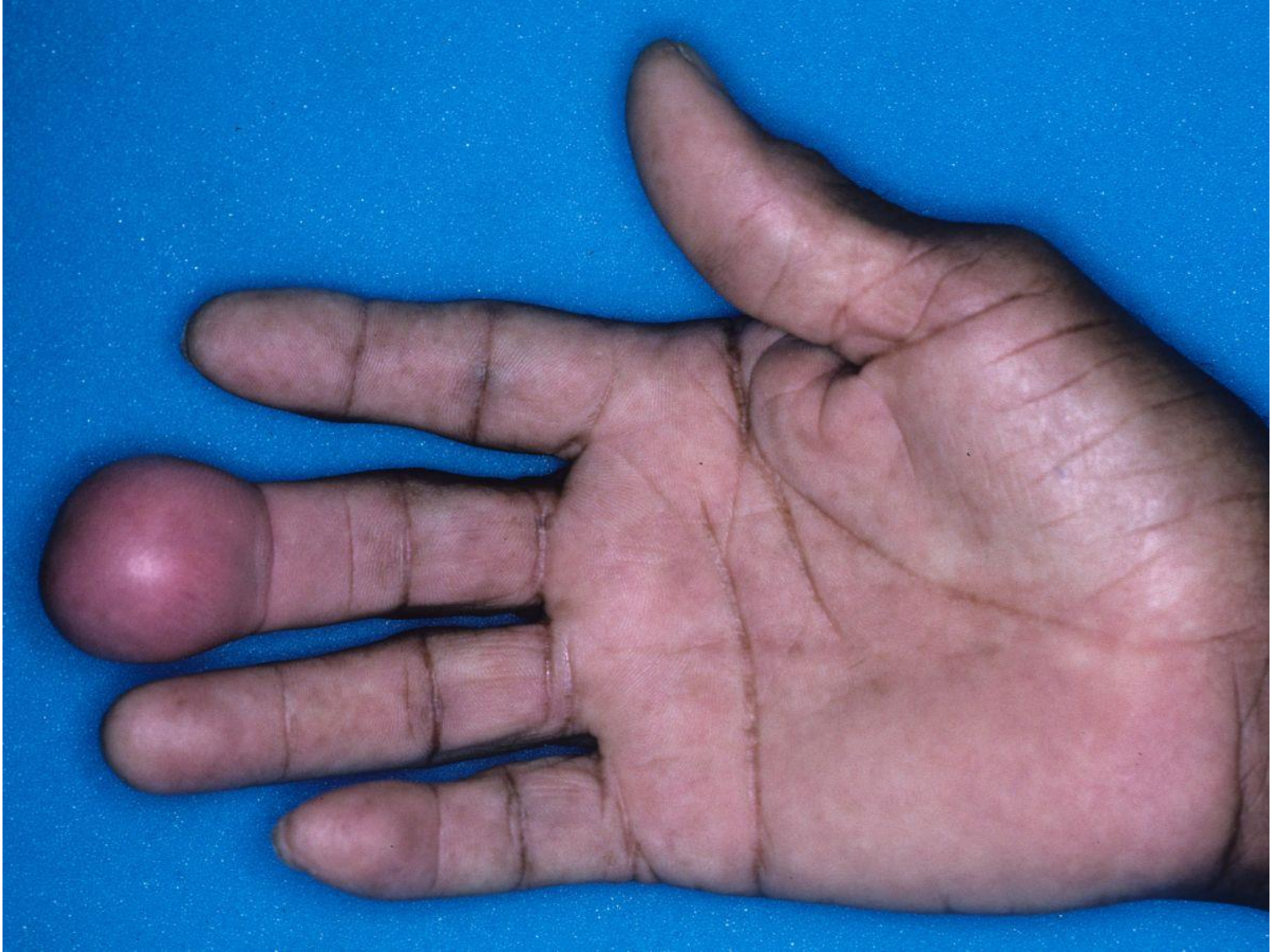FINGER (sagittal section)

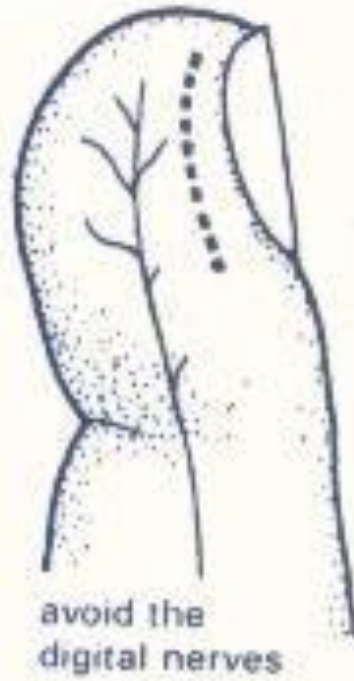

FINGER (longitudinal section)

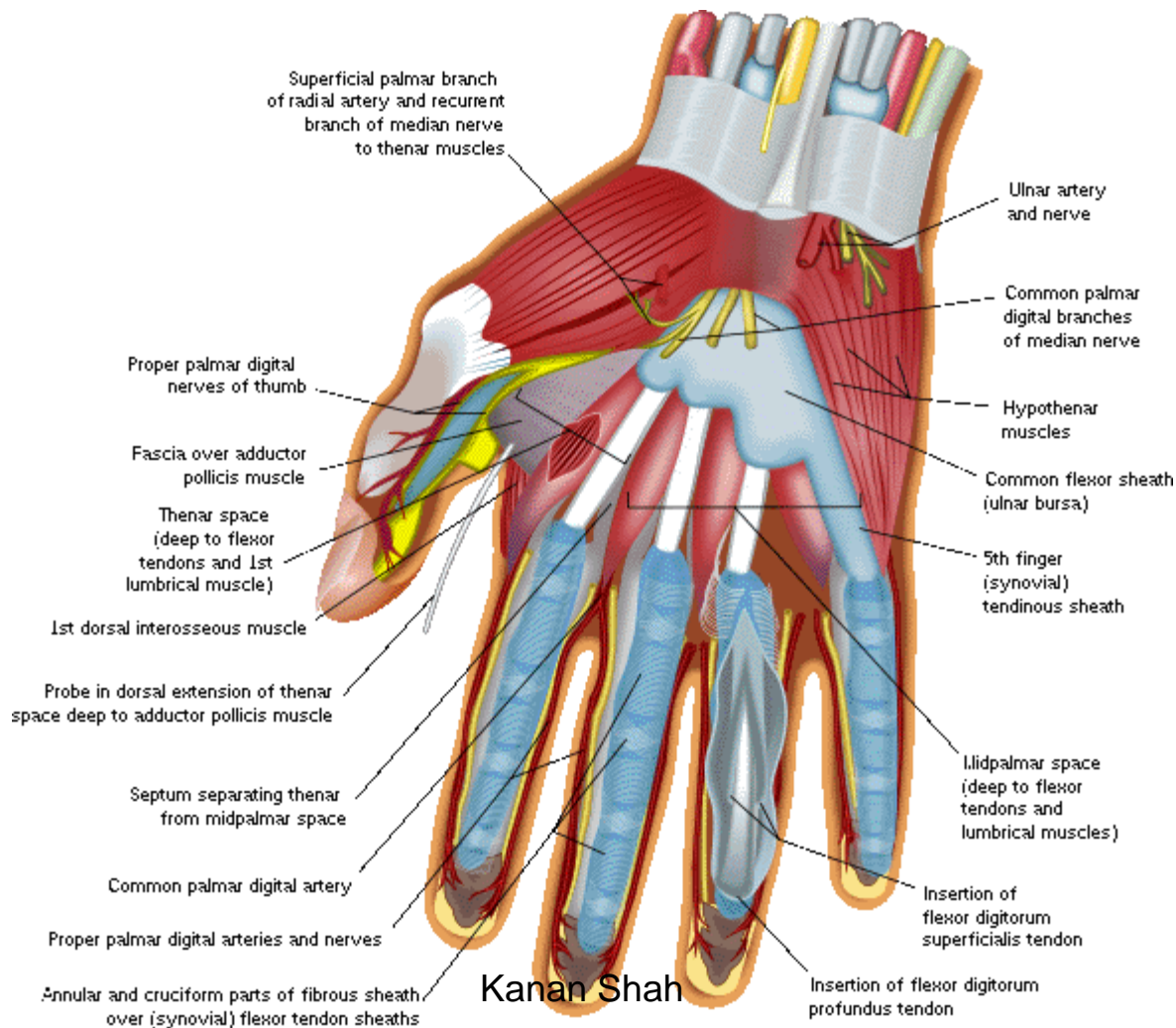


Proximal





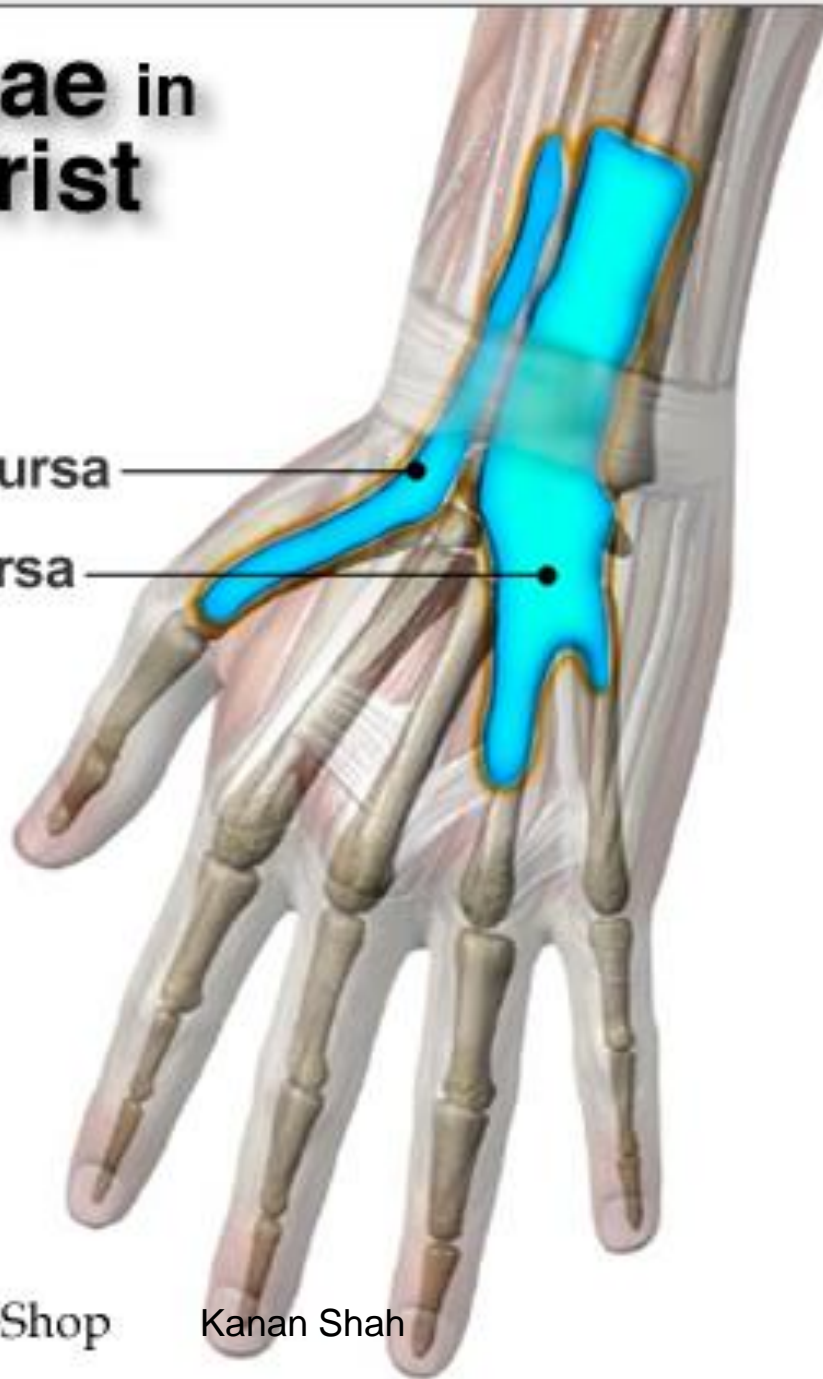DIGITAL SYNOVIAL SHEATH

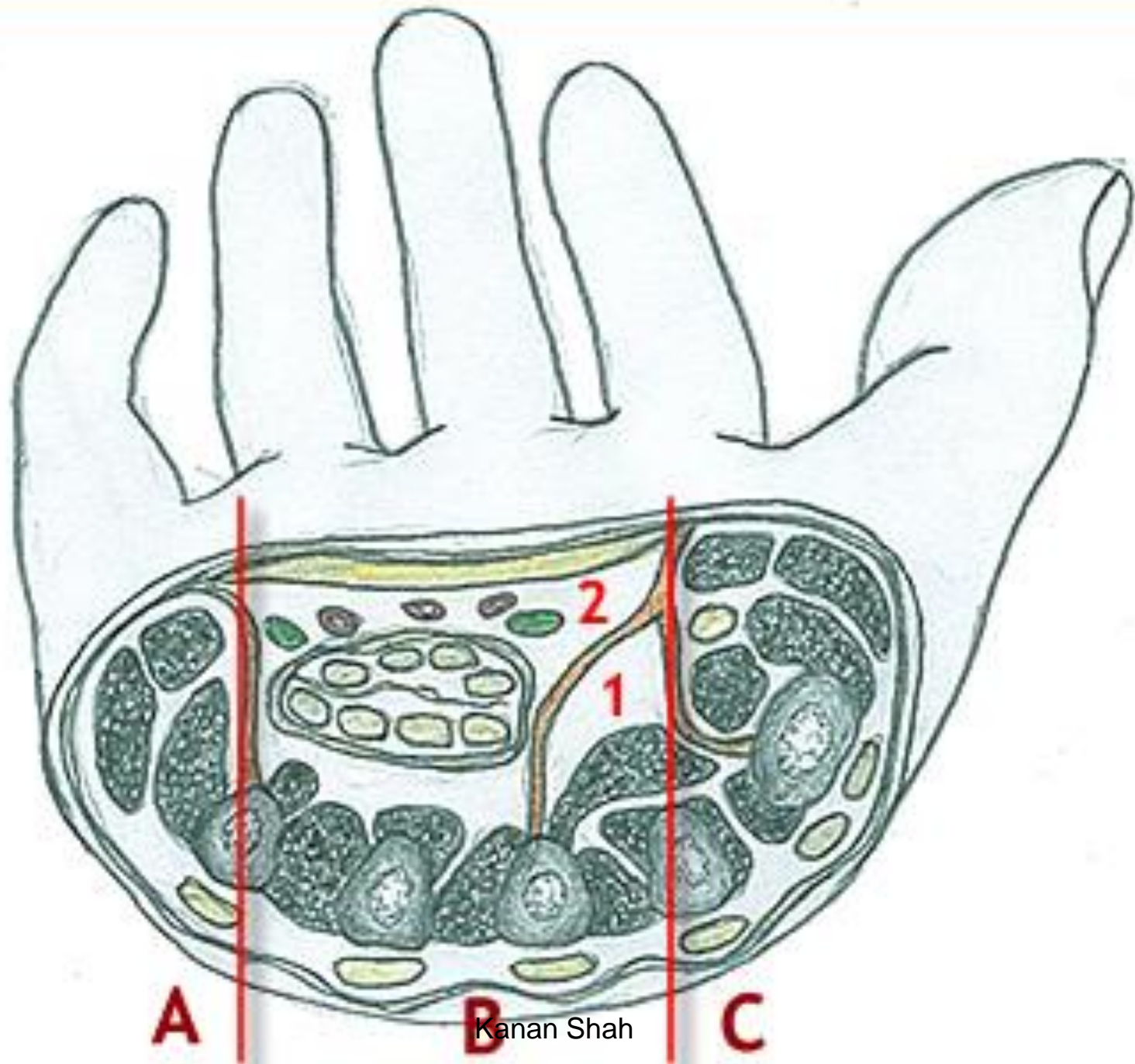


Bursae in the Wrist

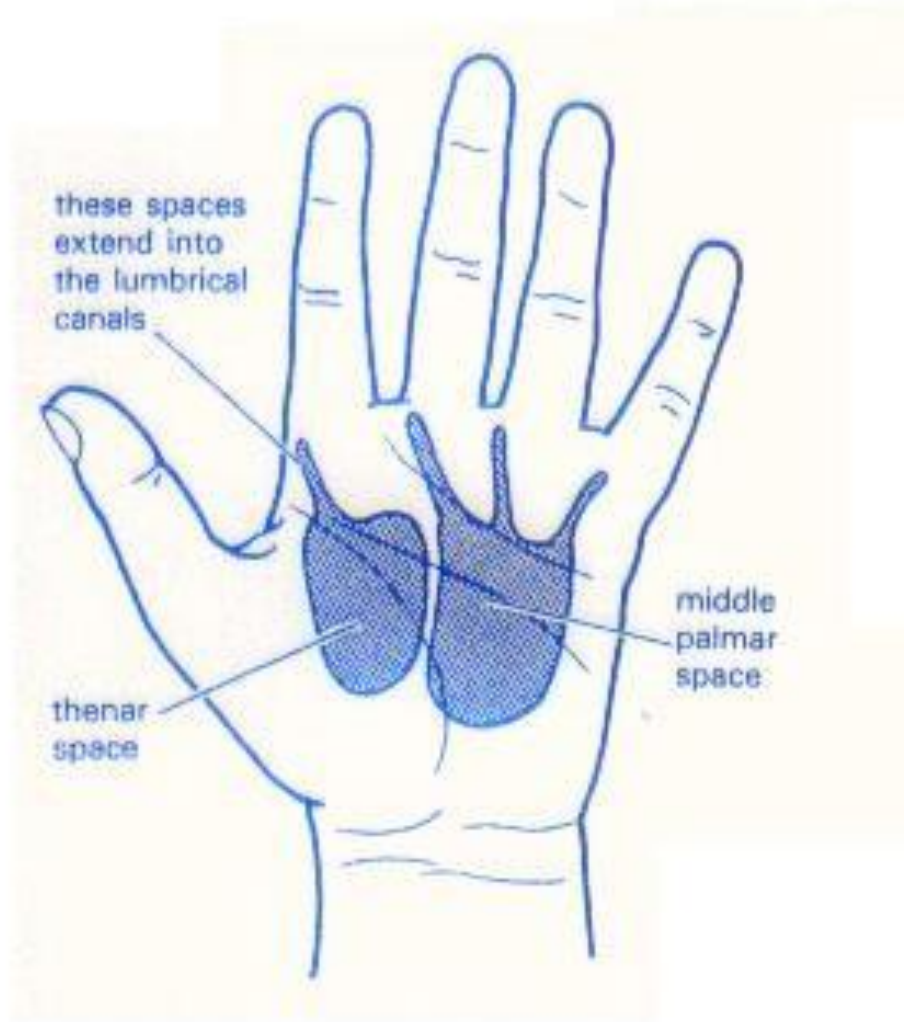
radial bursa

ulnar bursa

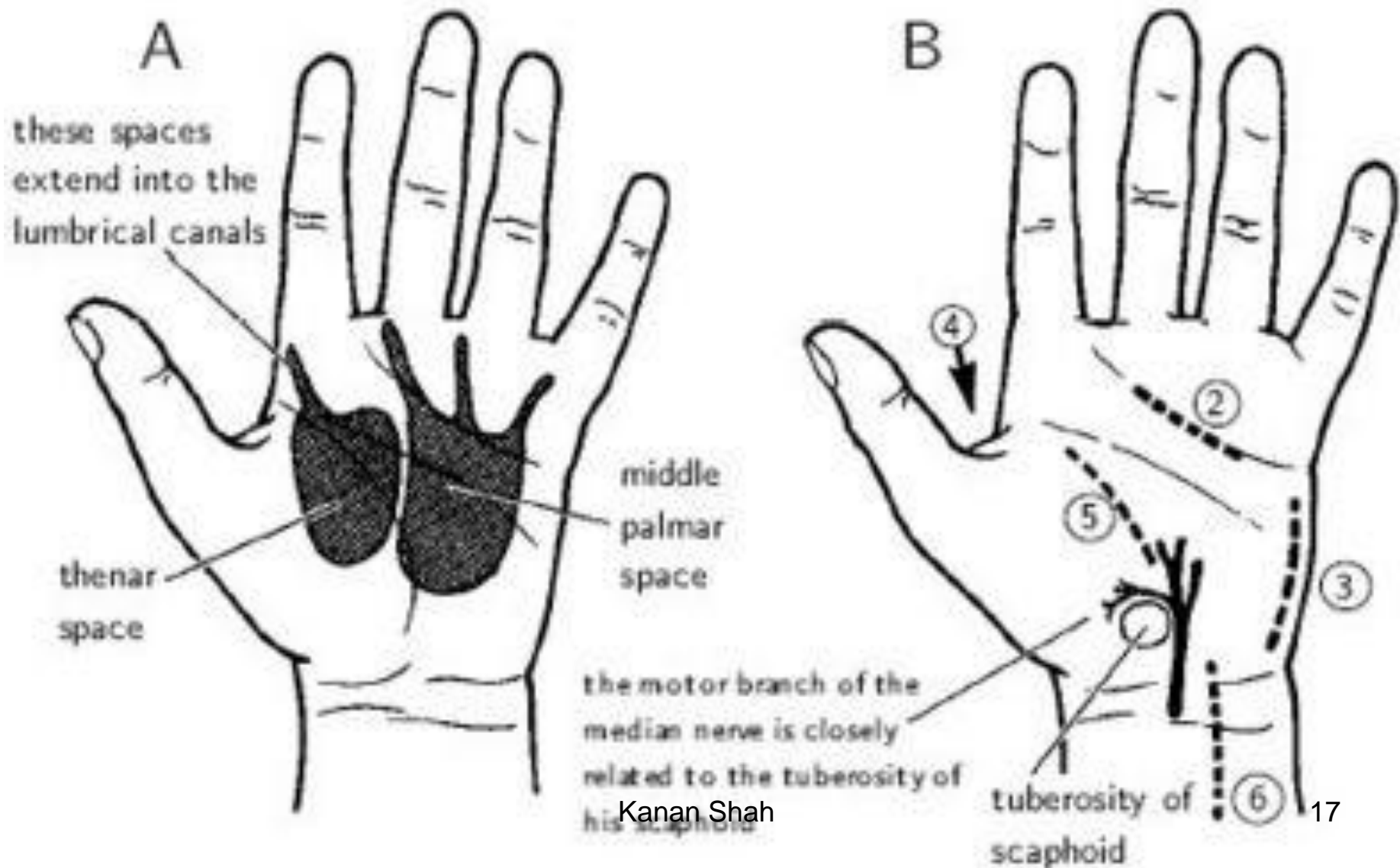


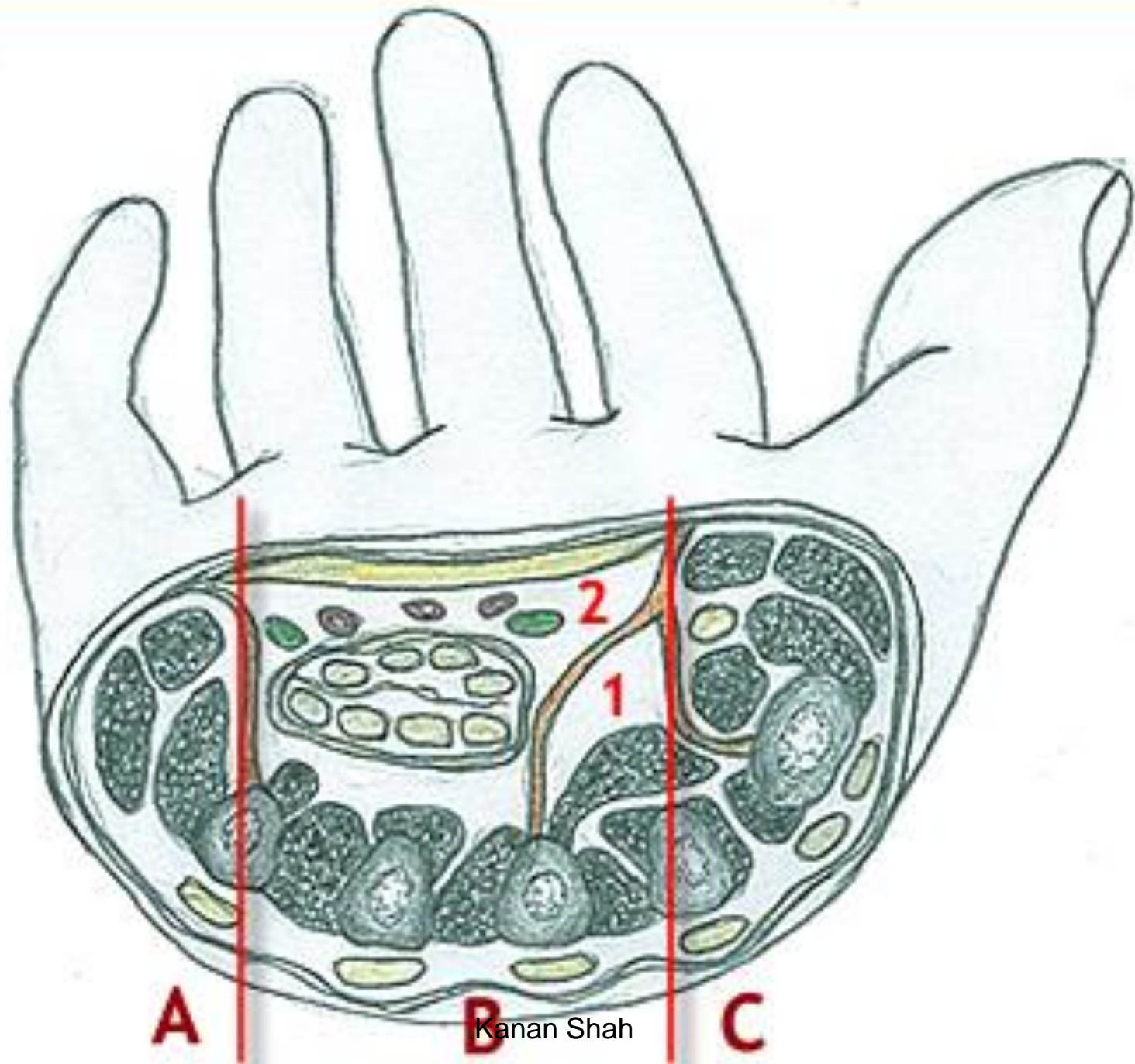


Kanan Shah



THE THENAR AND THE MIDDLE PALMAR SPACES





Kanan Shah

MIDPALMAR SPACE

SHAPE Triangular

SITUATION:

Under the inner half of the hollow of the palm.

EXTENT:

Proximal- Distal margin of the flexor retinaculum.

Distal- Distal palmar crease

COMMUNICATION:

Proximal- Forearm space

Distal- Fascial sheaths of the 3rd and 4th lumbricals. Occ.2nd

BOUNDARIES.

SOURCE OF INFECTION

DRAINAGE:

THENAR SPACE

Triangular

Under the outer half of the hollow of the palm.

Distal margin of the flexor retinaculum.

Proximal transverse palmar crease.

.

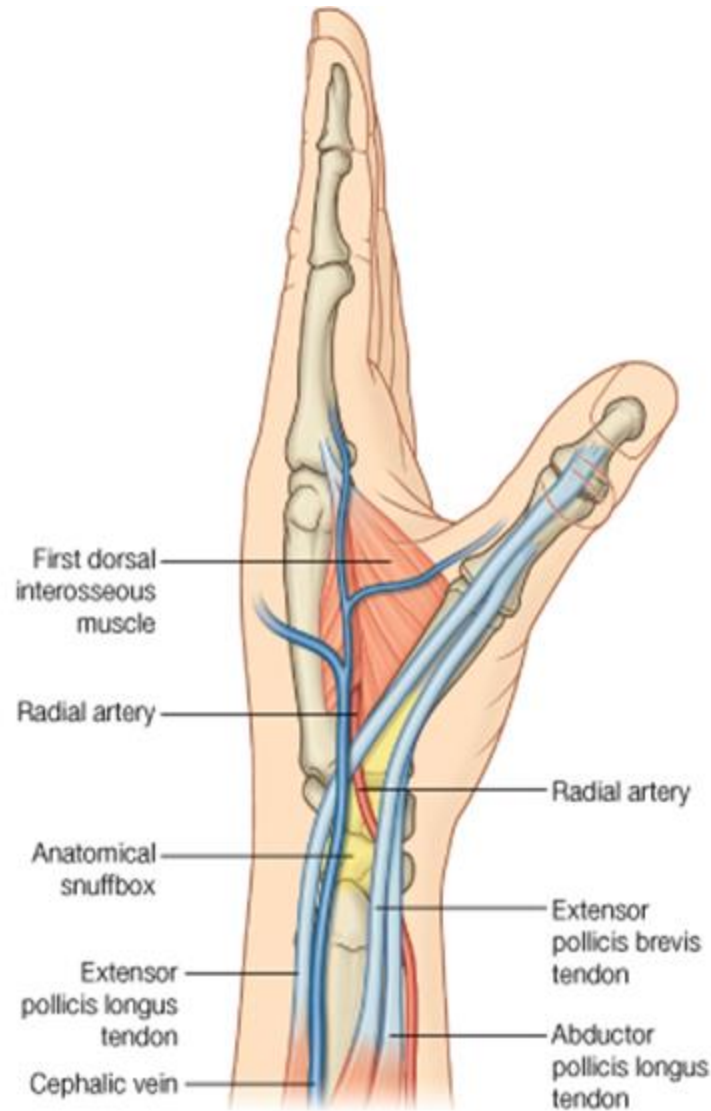
Fascial sheaths of the 1st lumbricals. Occ.2nd.

DORSAL SPACES

- Dorsal subcutaneous space
- Dorsal subaponeurotic space

APPLIED ANATOMY

- WHITLOW
- COMPOUND PALMER GANGLION
- SURGICAL INCISIONS OF HAND



© Elsevier. Drake et al: Gray's Anatomy for Students - www.studentconsult.com

Aknowledgements

- Human Anatomy by BD Chaurasia
- Gray's Anatomy
- Essentials of Human Antomy: Upper Limb and Lower Limb by Asimkumar Dutta