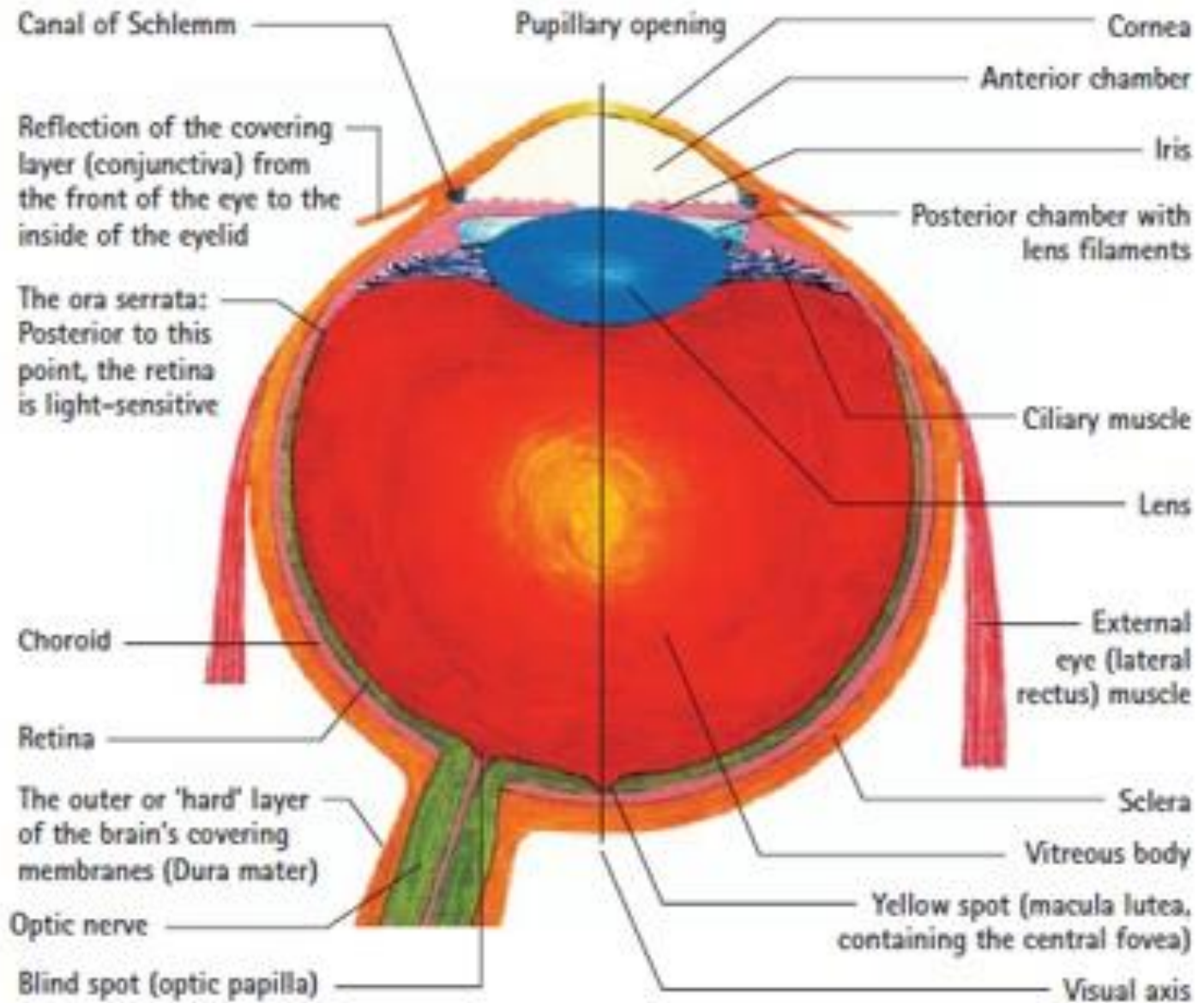
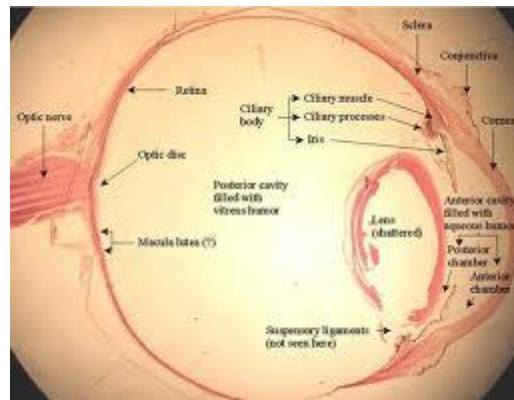
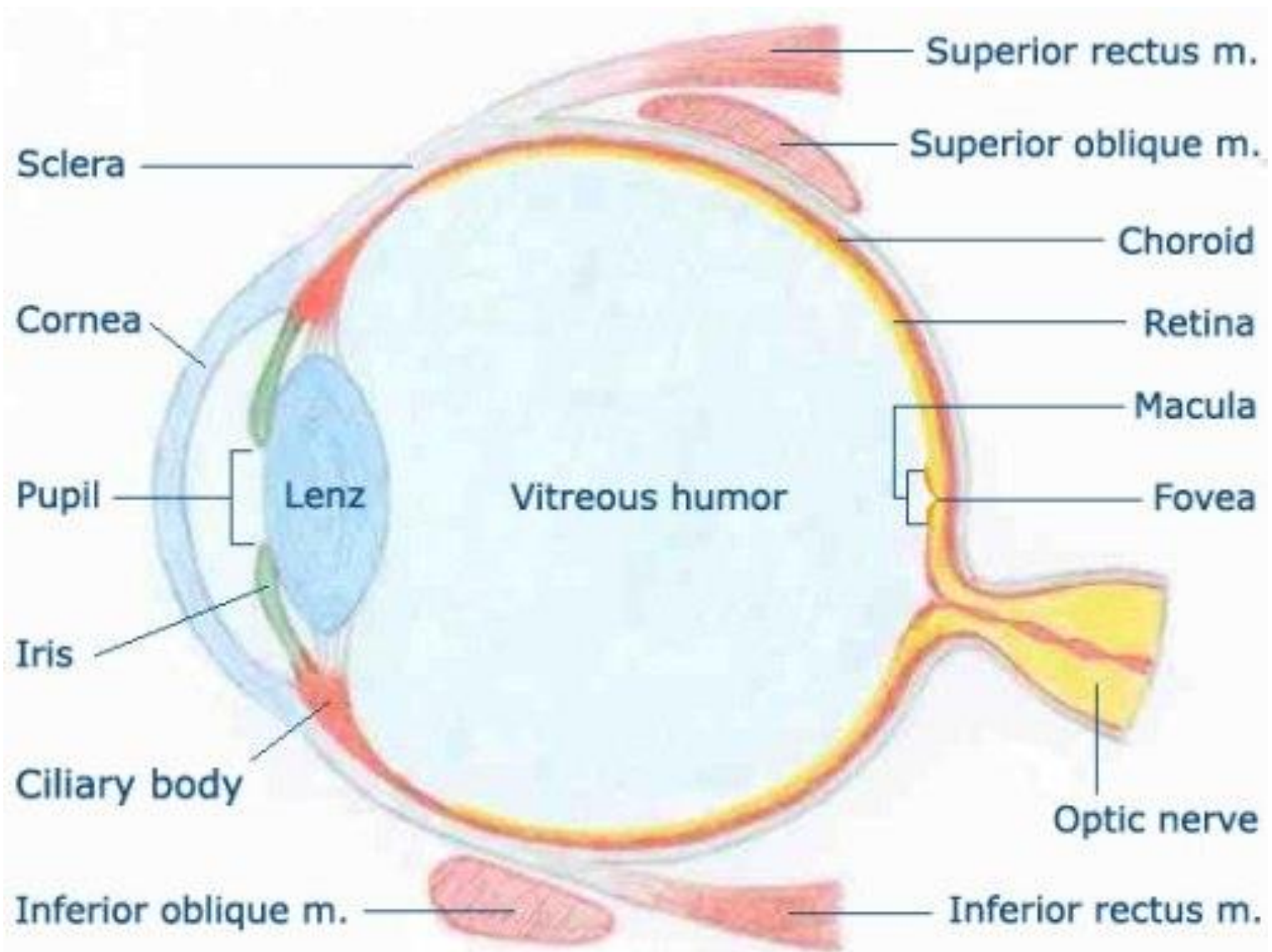


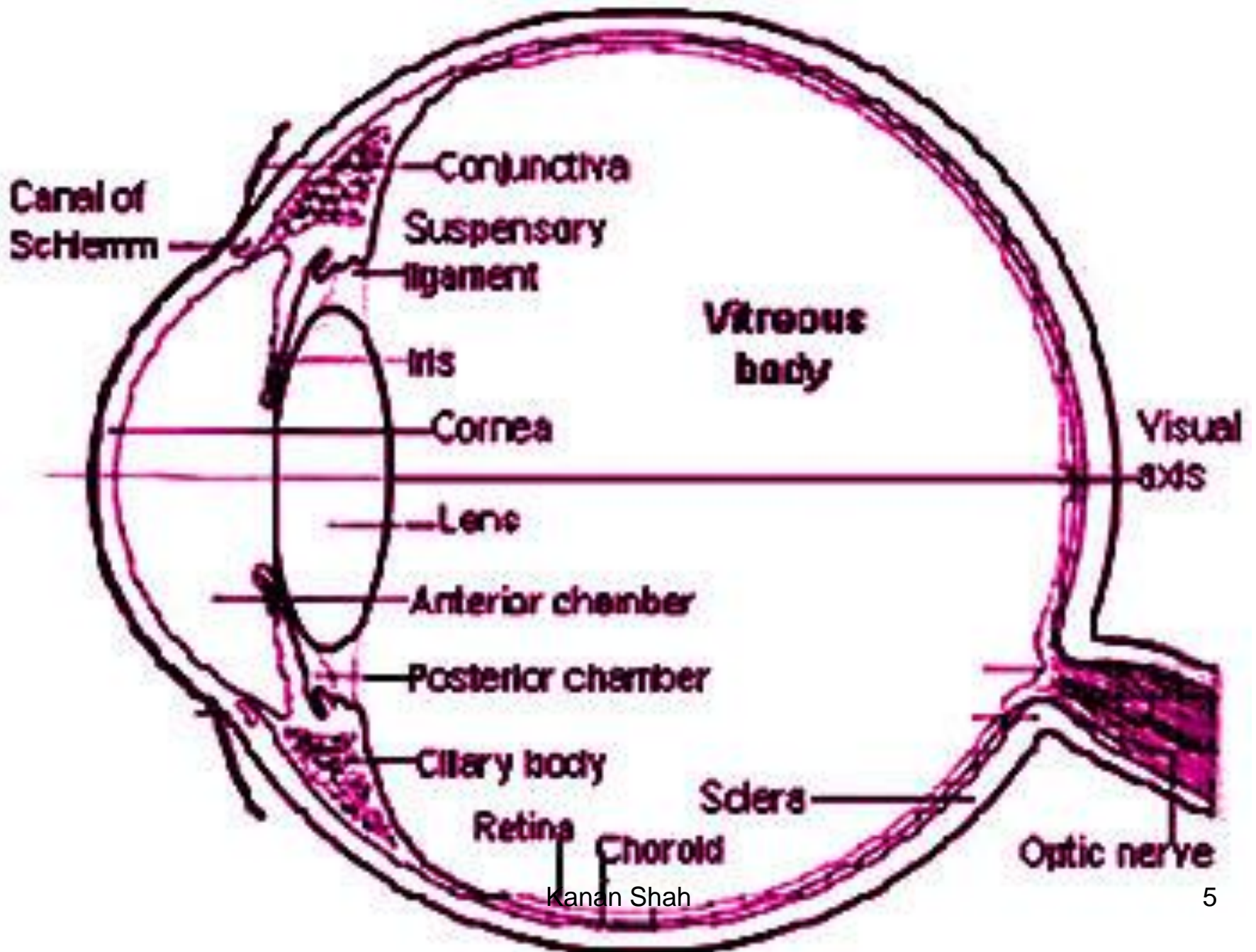
EYE & EAR







© ForBestVision.com

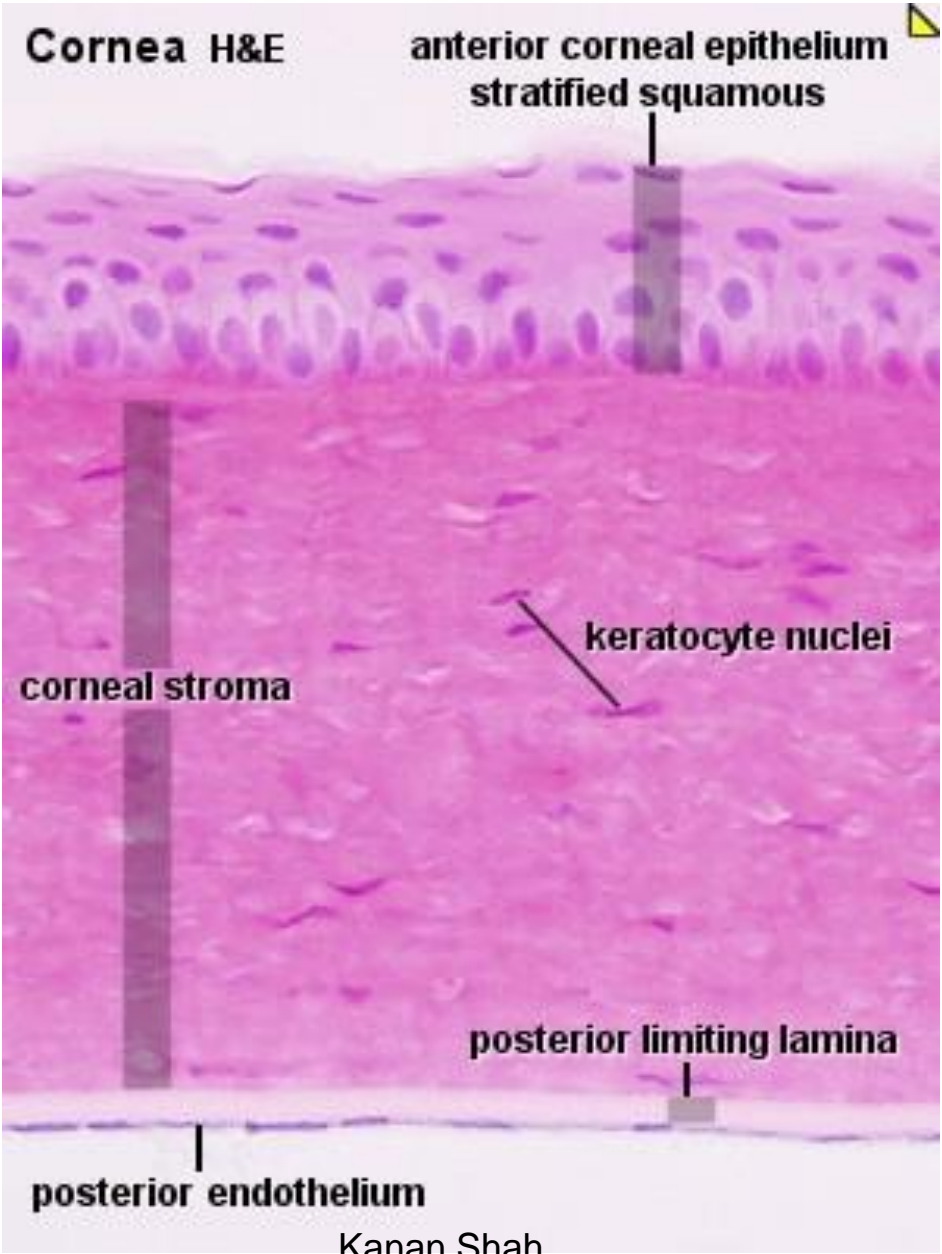


EYE LID

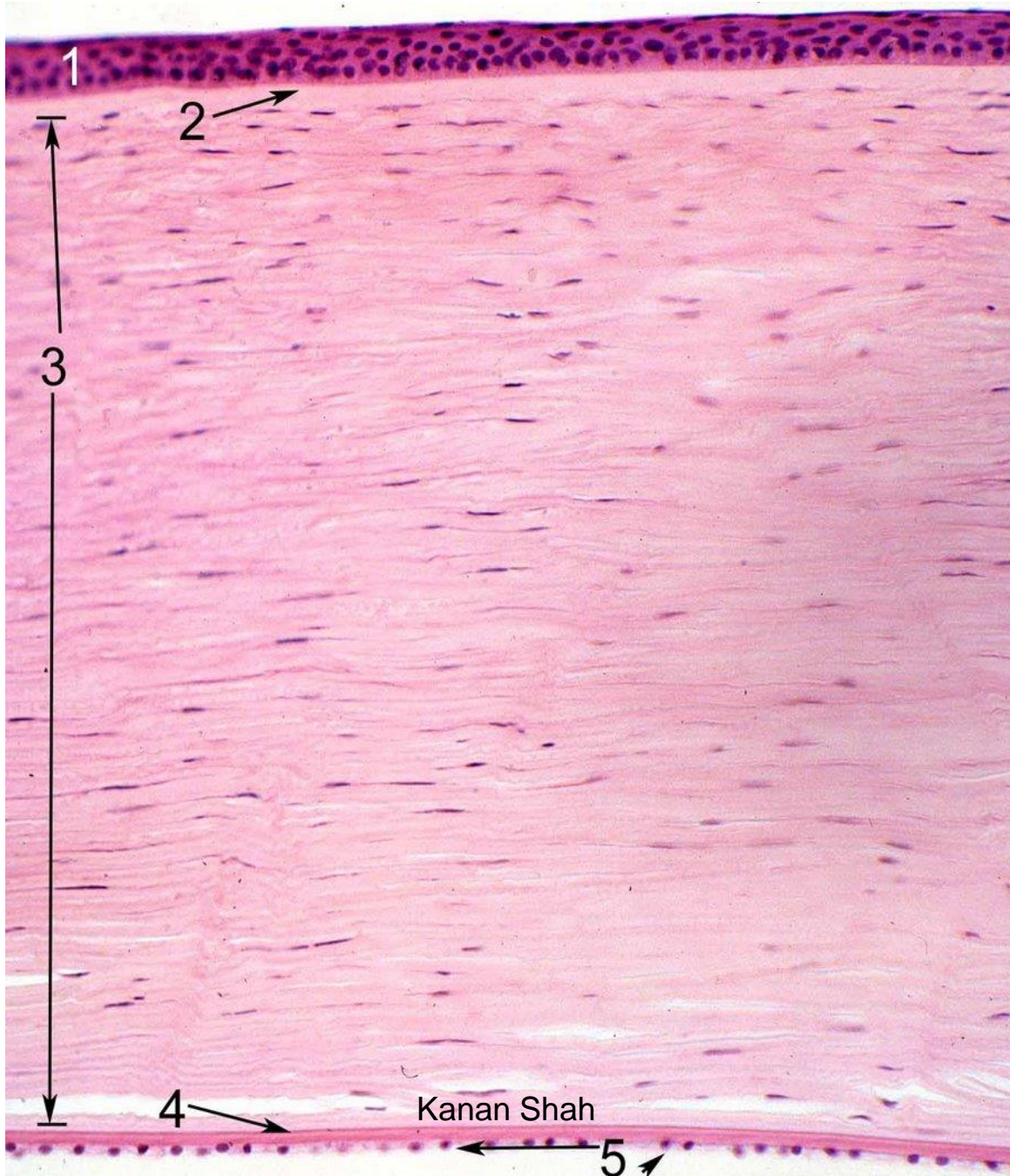
- SKIN
- SUBCUTANEOUS TISSUE
- ORBICULARIS OCULI
- LOOSE AREOLAR TISSUE
- DENSE FIBROUS TISSUE TARSAL PLATE
- TARSAL GLANDS
- CONJUNCTIVA

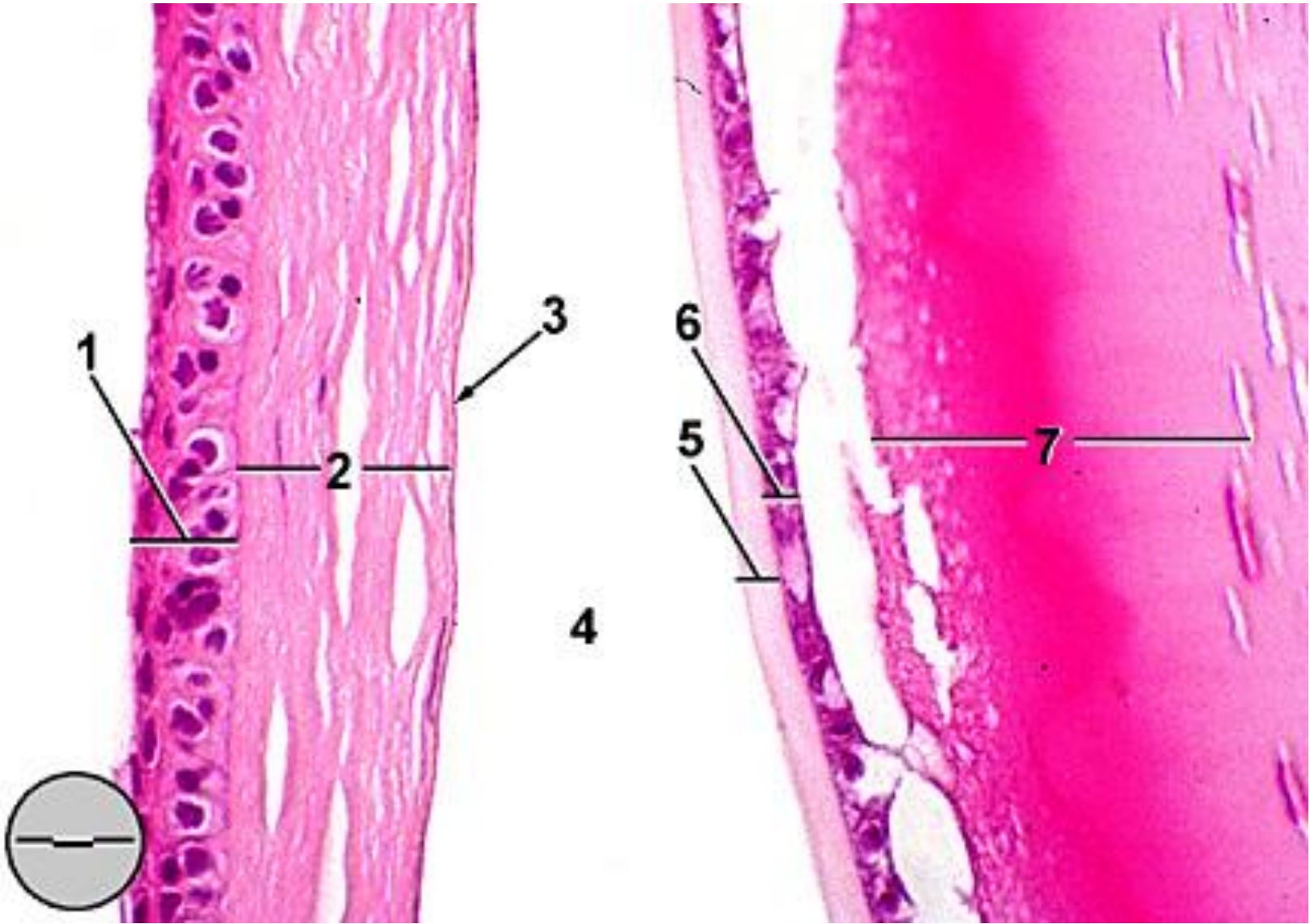
CORNEA

- CORNEAL EPITHELIUM
- BOWMAN'S MEMBRANE
- SUBSTANTIA PROPRIA
- DESCEMENT'S MEMBRANE
- MESOTHELIUM

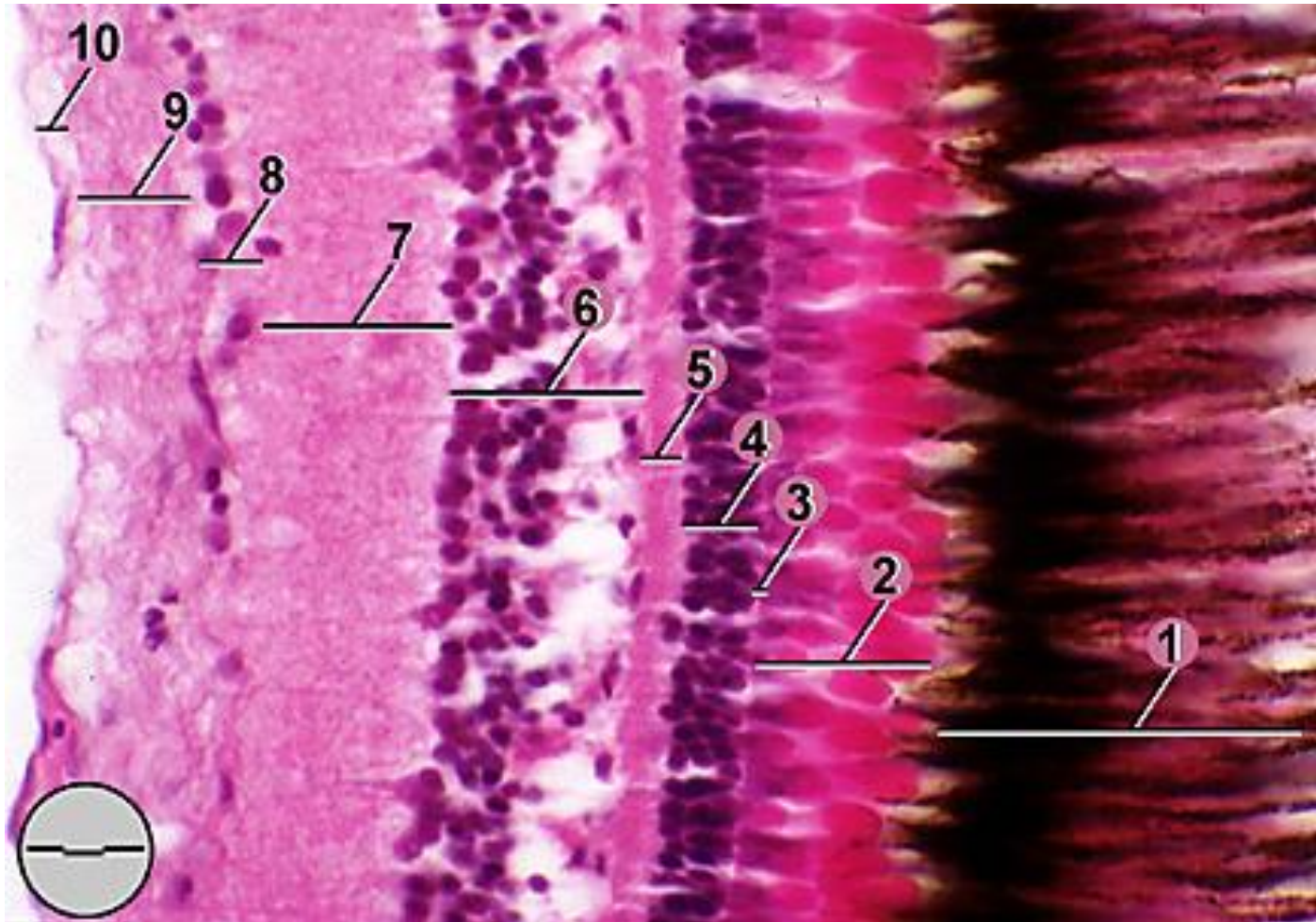


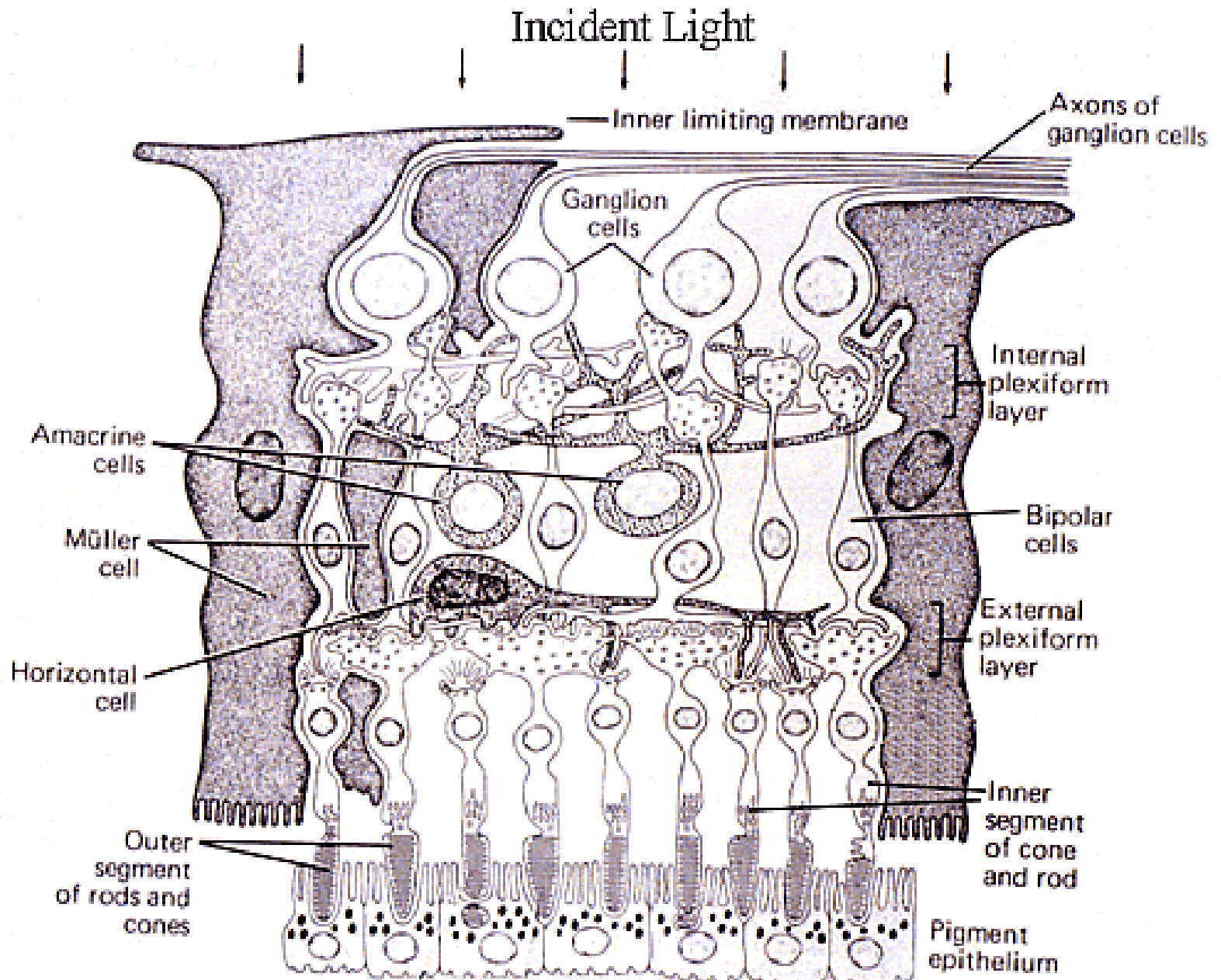
Kanan Shah

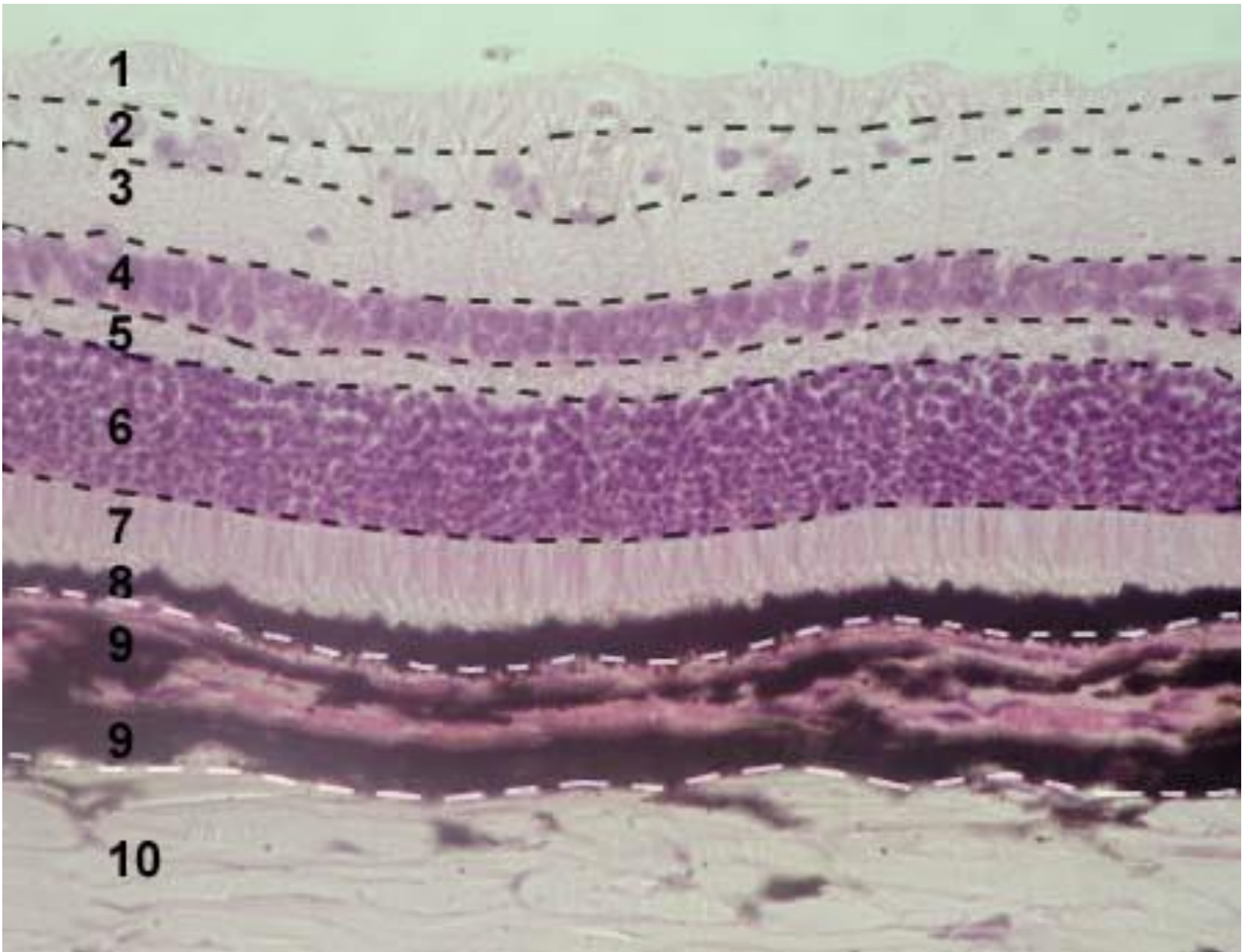




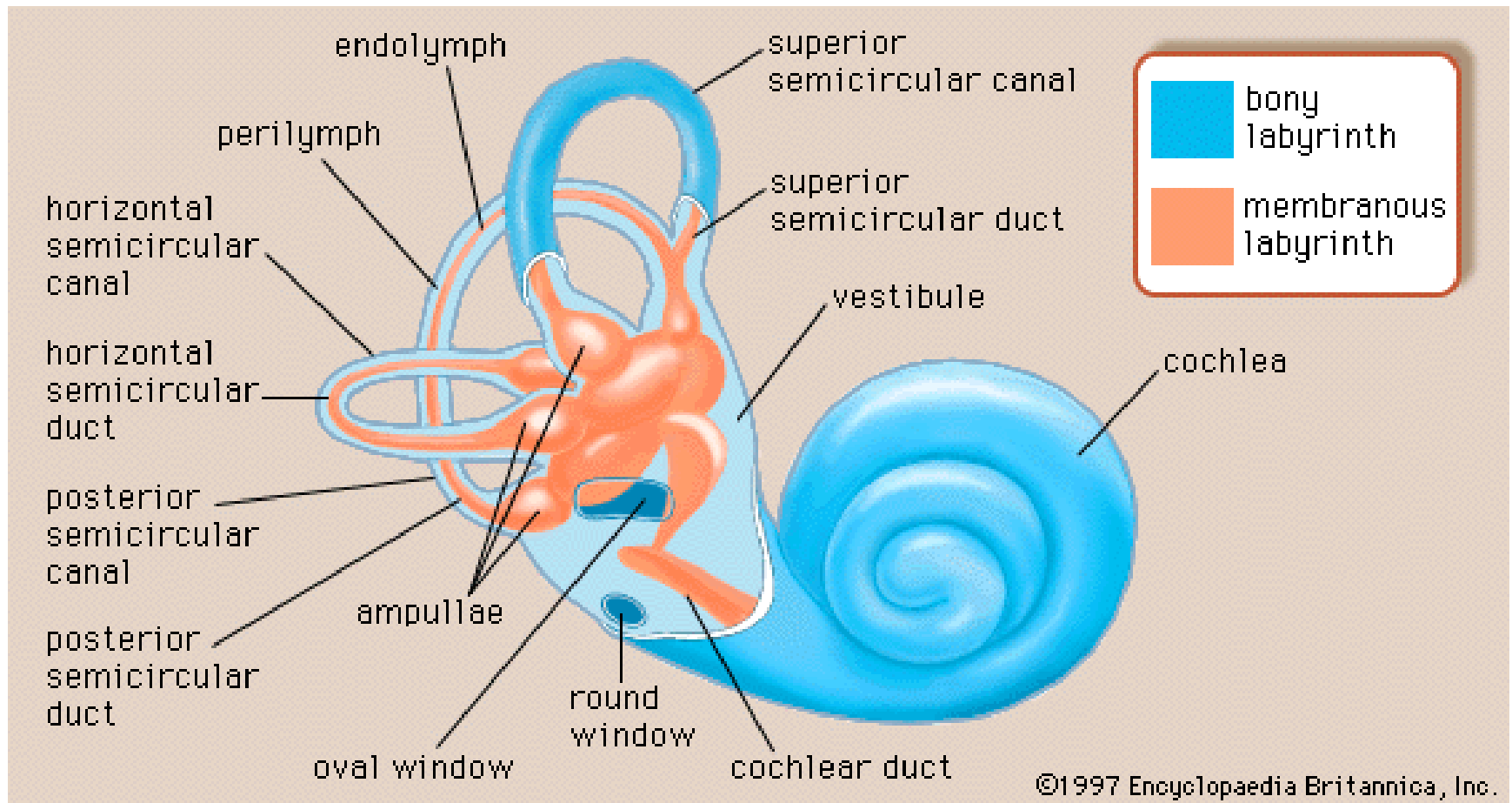
RETINA

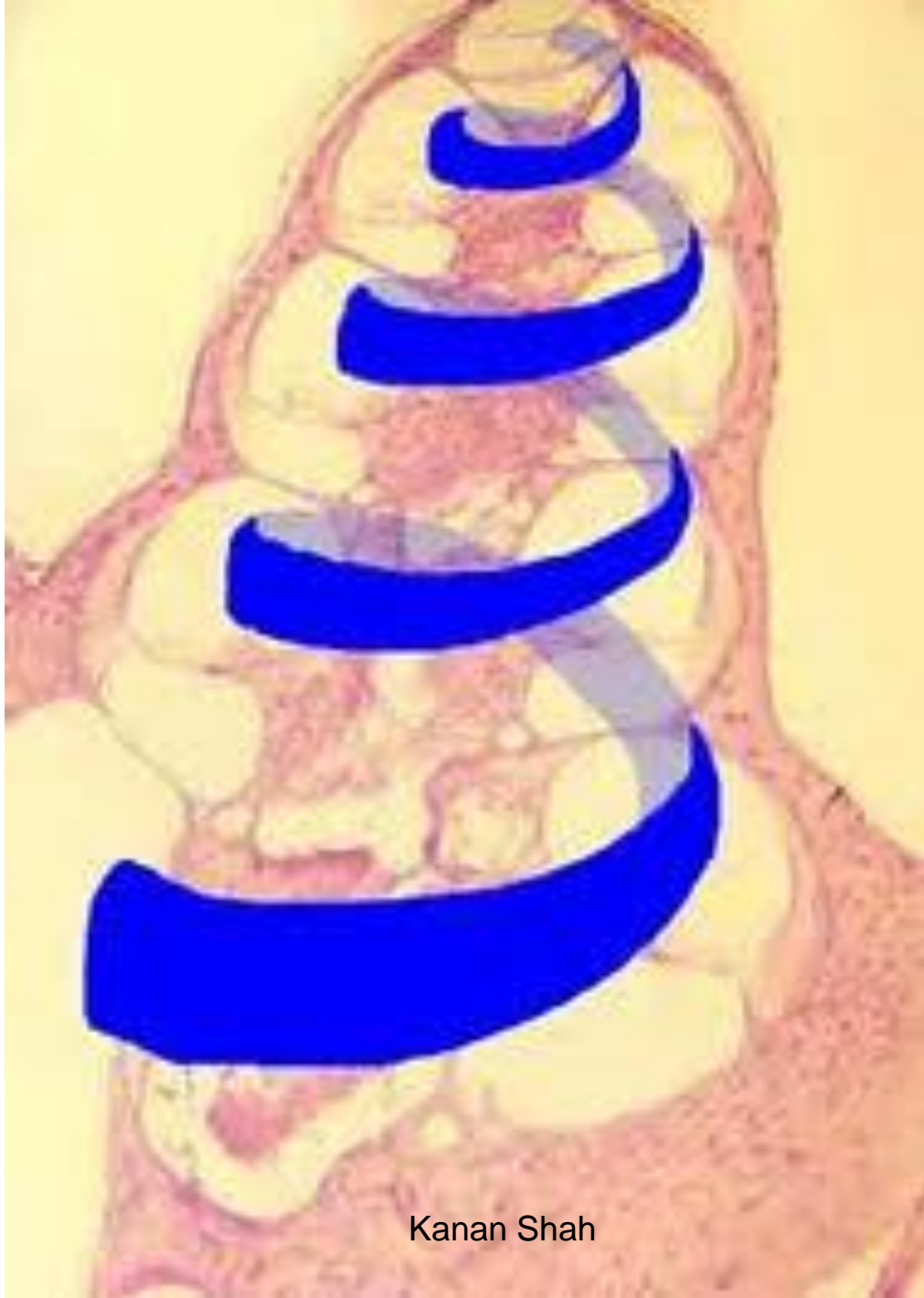




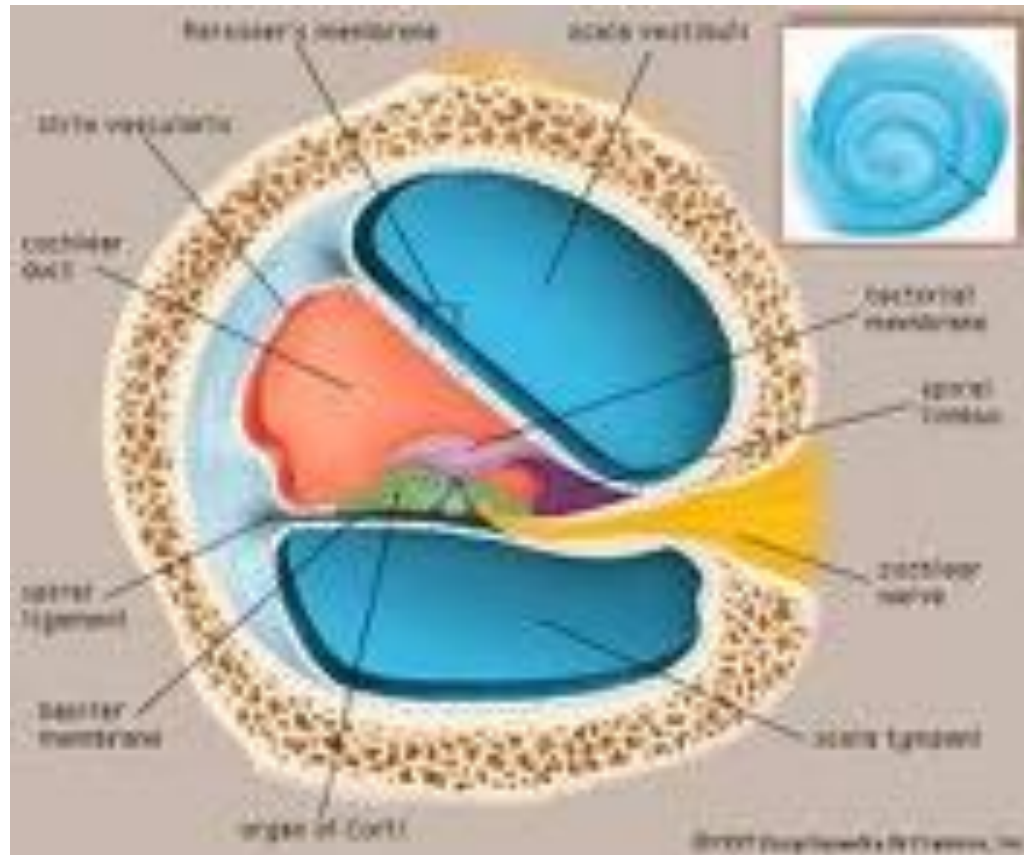


INTERNAL EAR

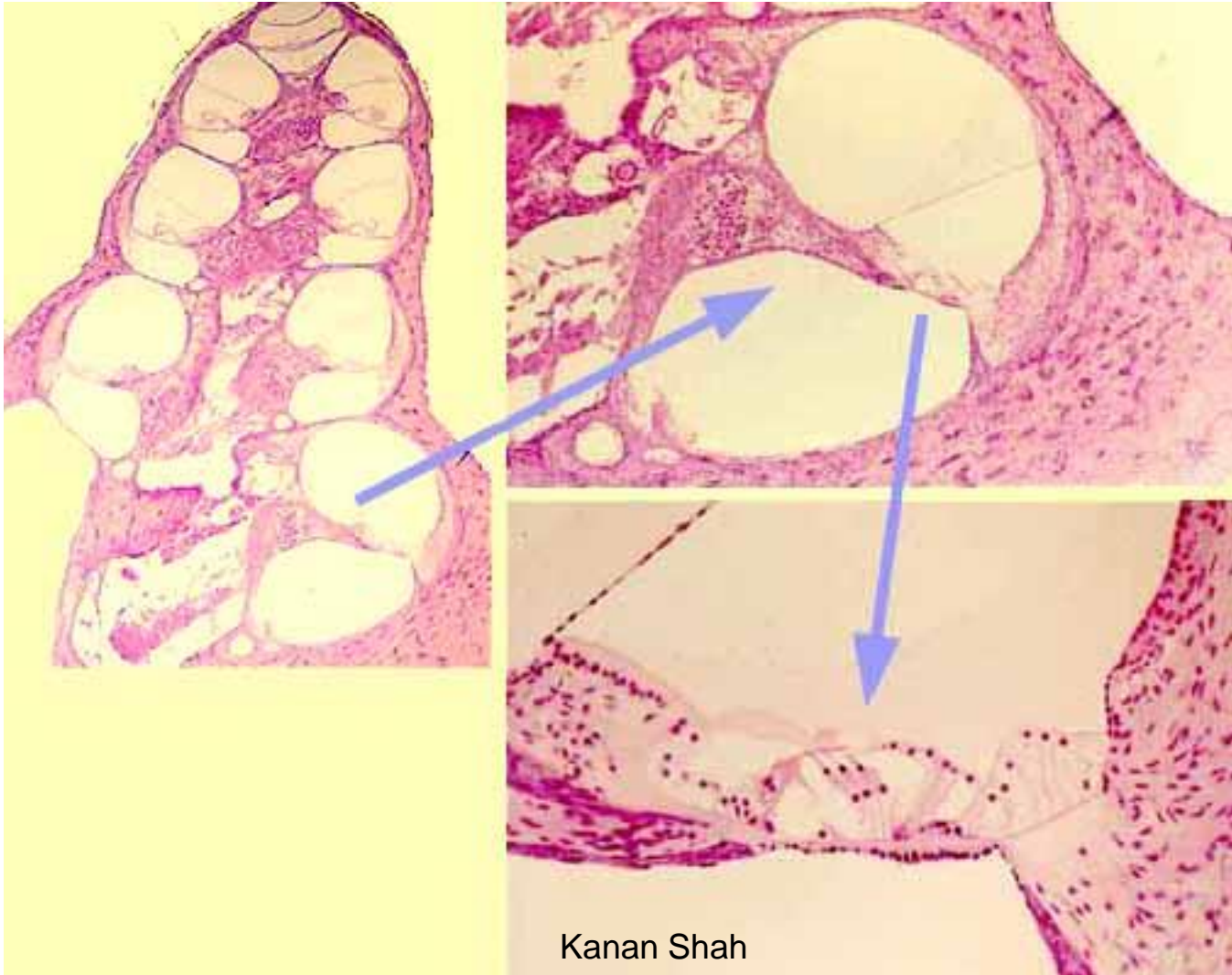


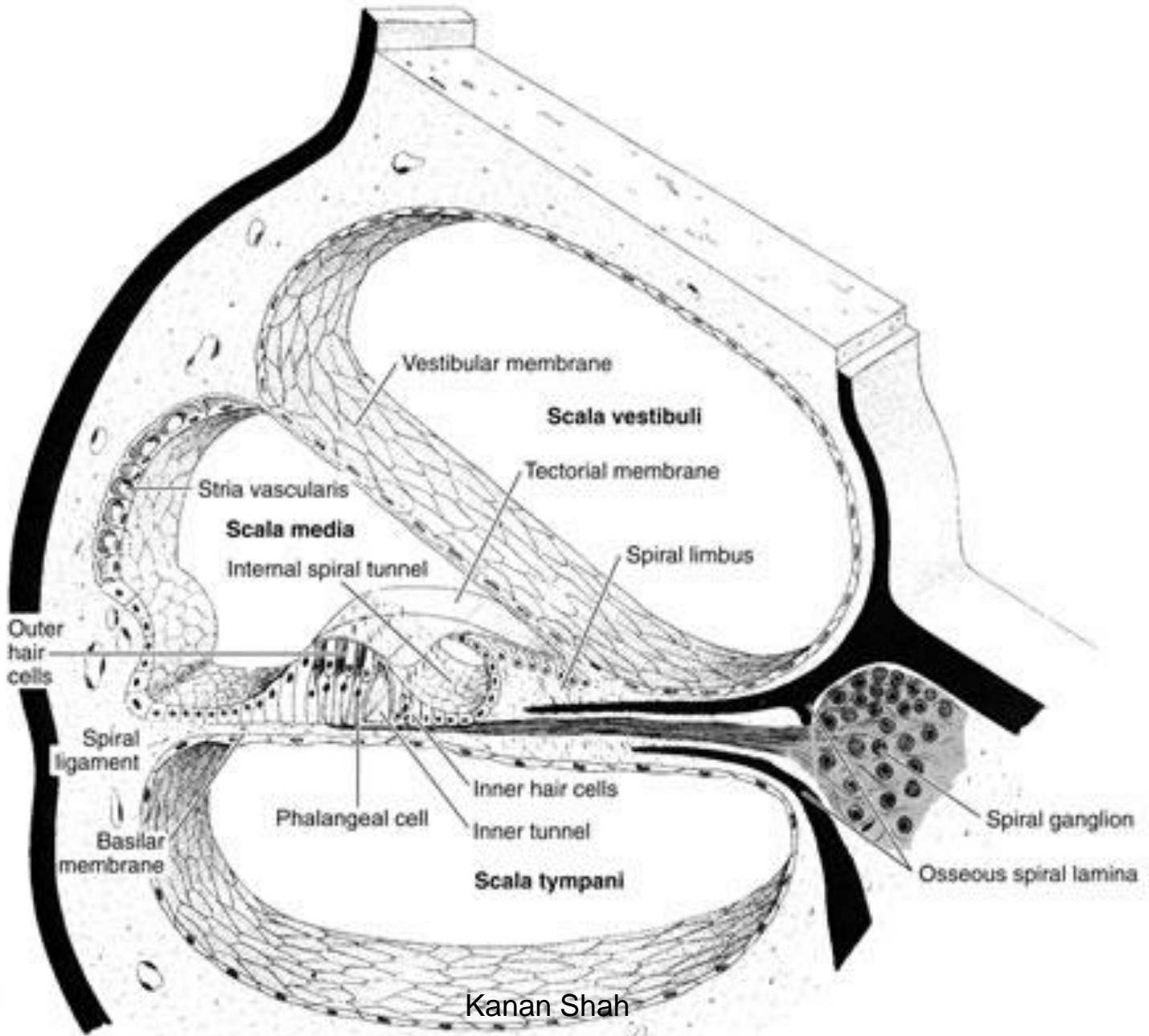


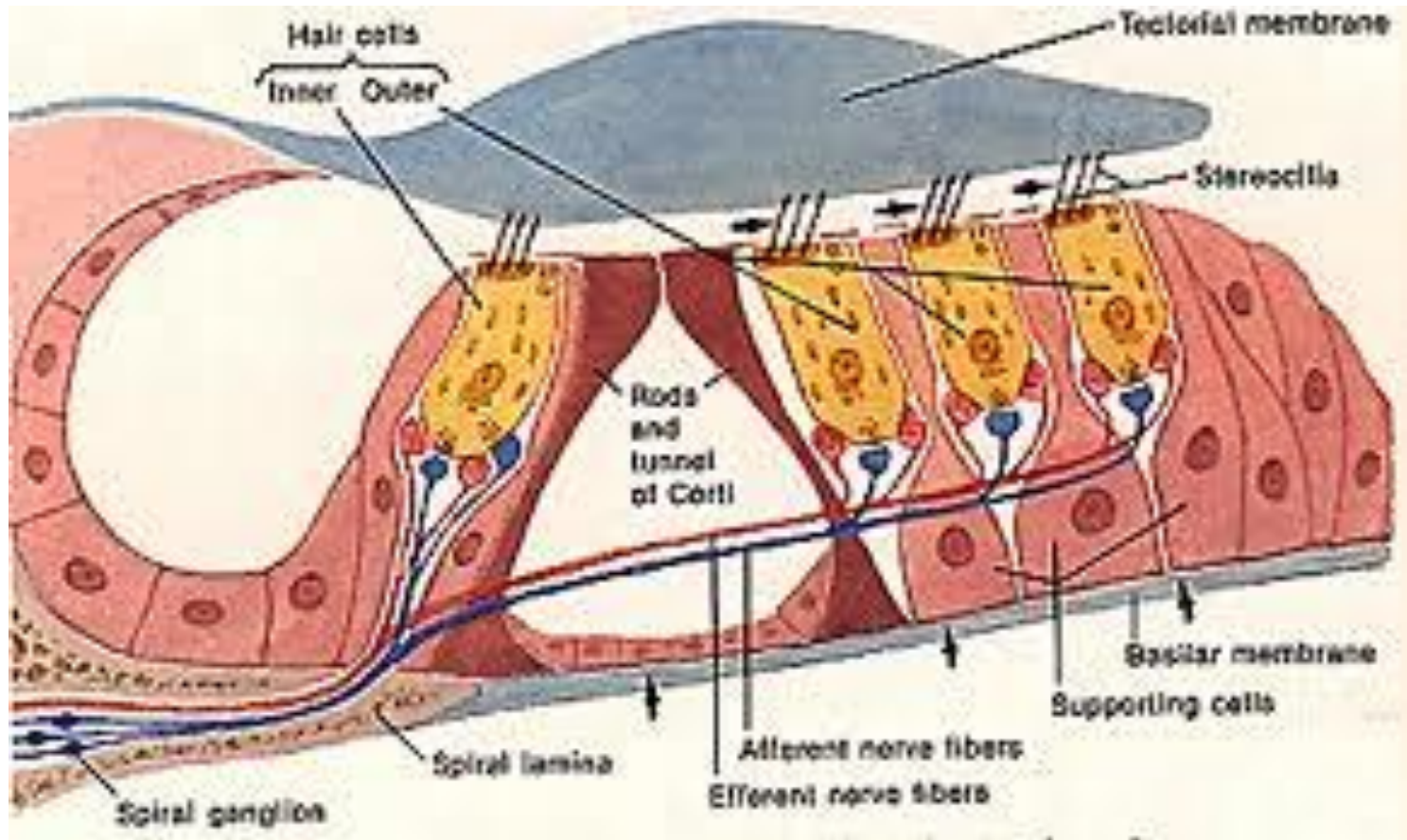
COCHLEAR CANAL

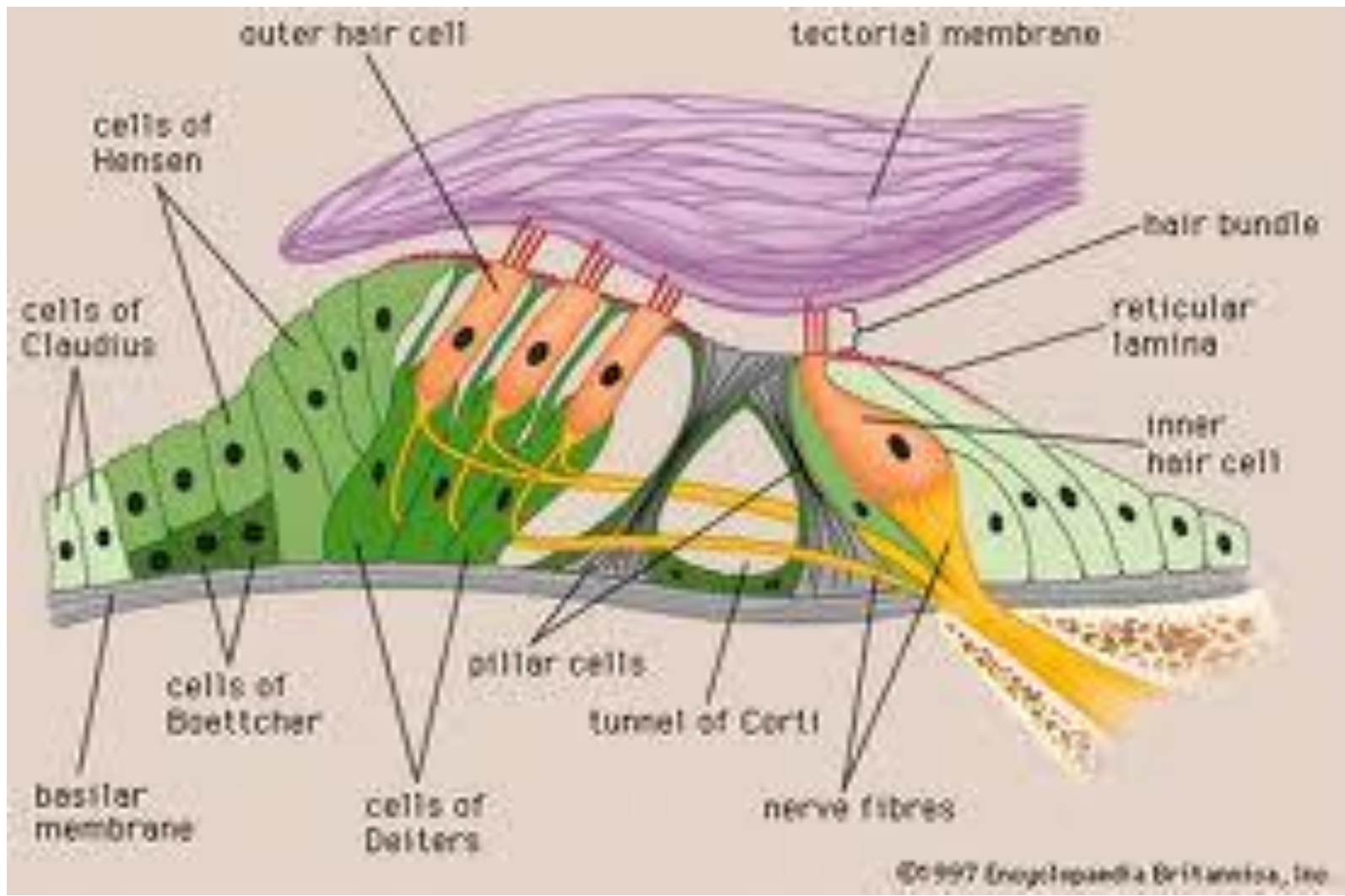


INNER EAR

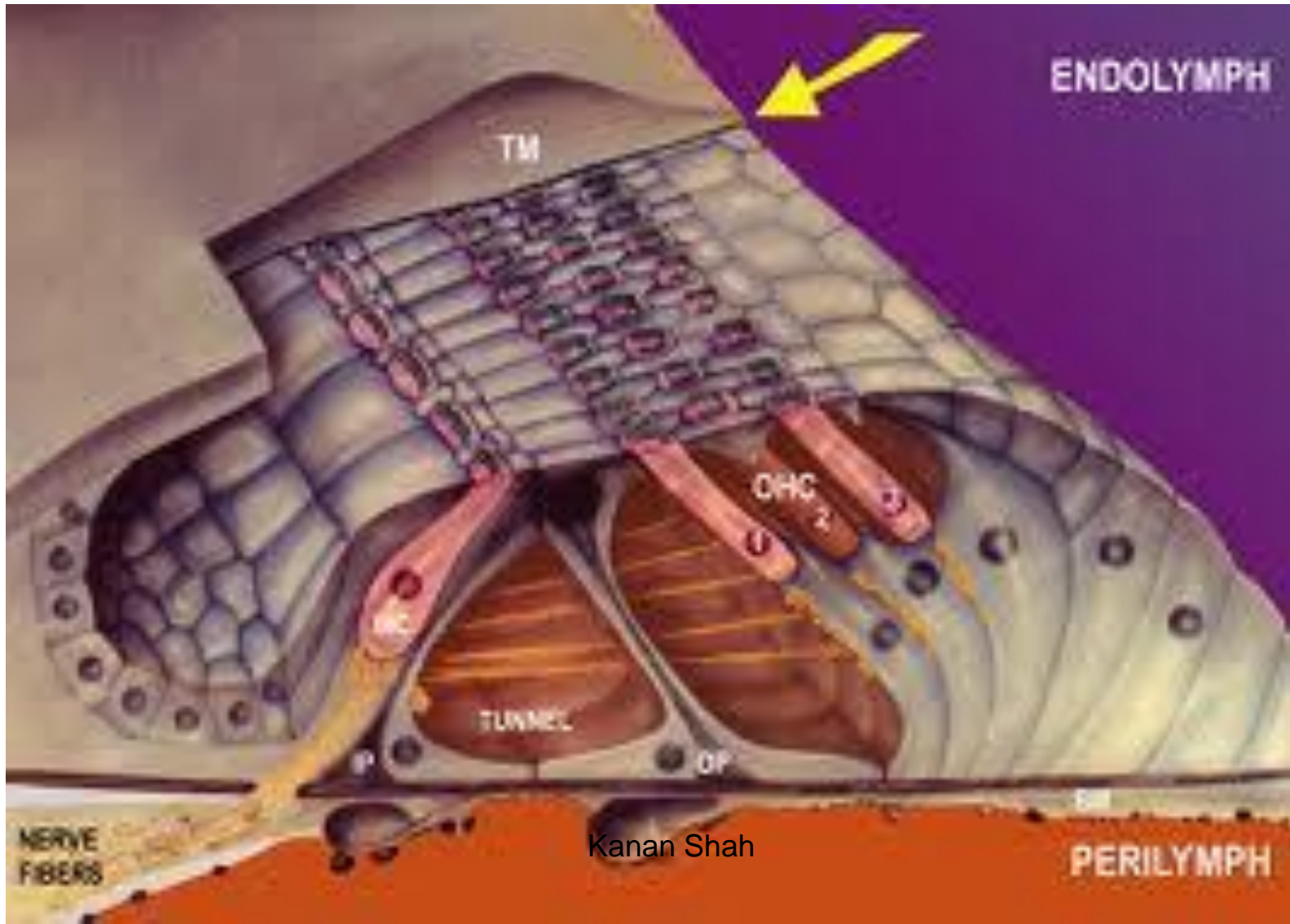








ORGAN OF CORTI



Aknowledgement

- Inderbir Singh's Textbook of Human Histology
- Textbook of Histology- Atlas and Practical Guide by JP Gunasegaran
- Difiore's Atlas of Histology
- Images from Google
- Histology Text & Atlas -Brijeshkumar