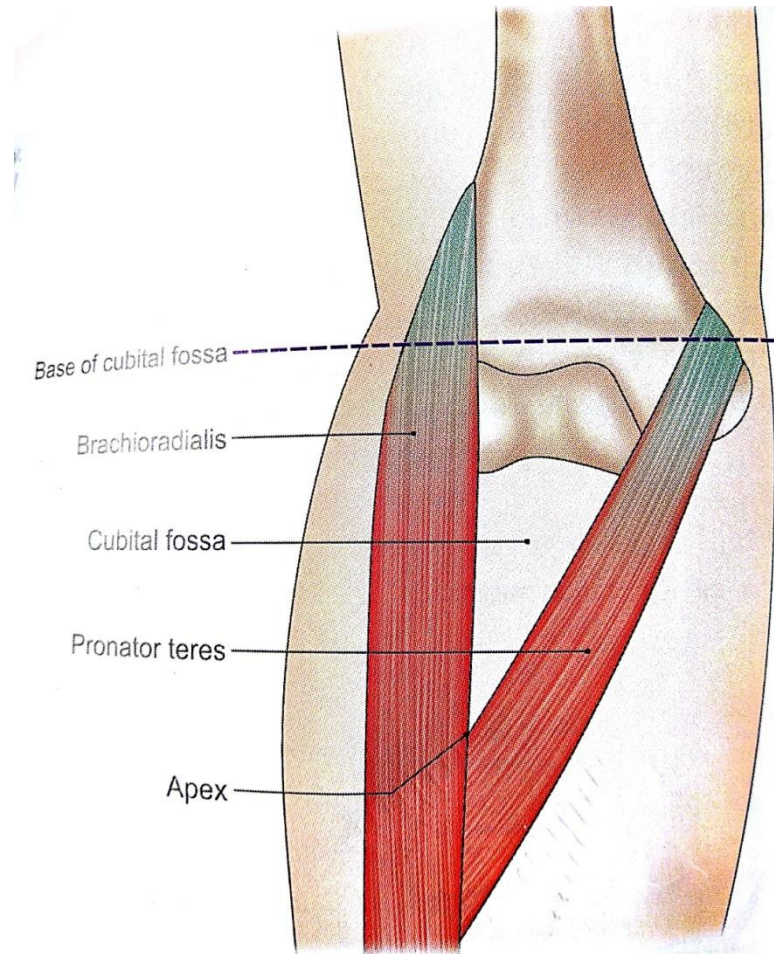


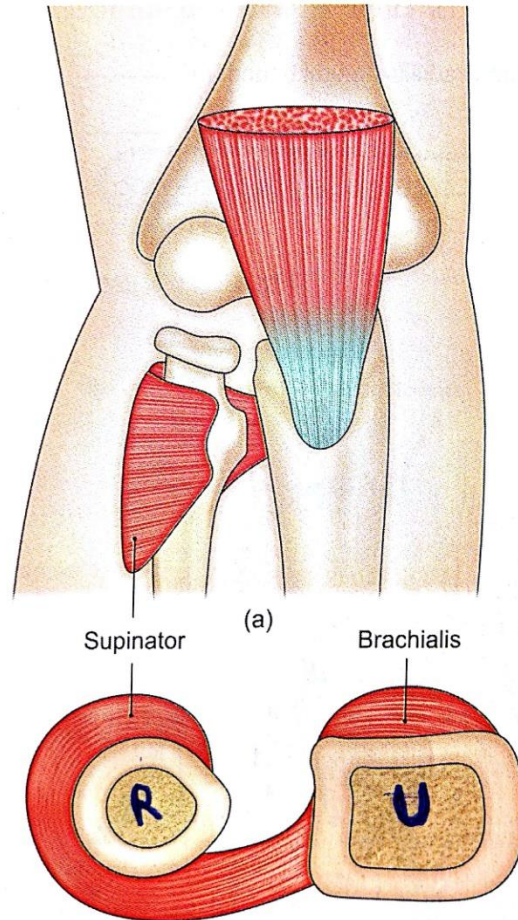
# CUBITAL FOSSA

Triangular hollow in front of elbow

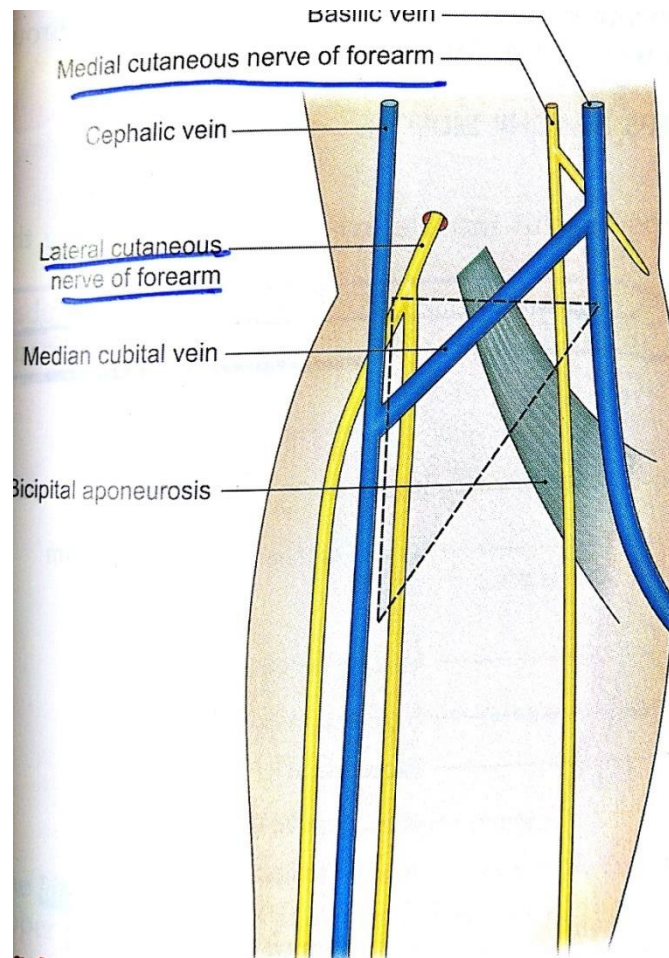
# Boundaries



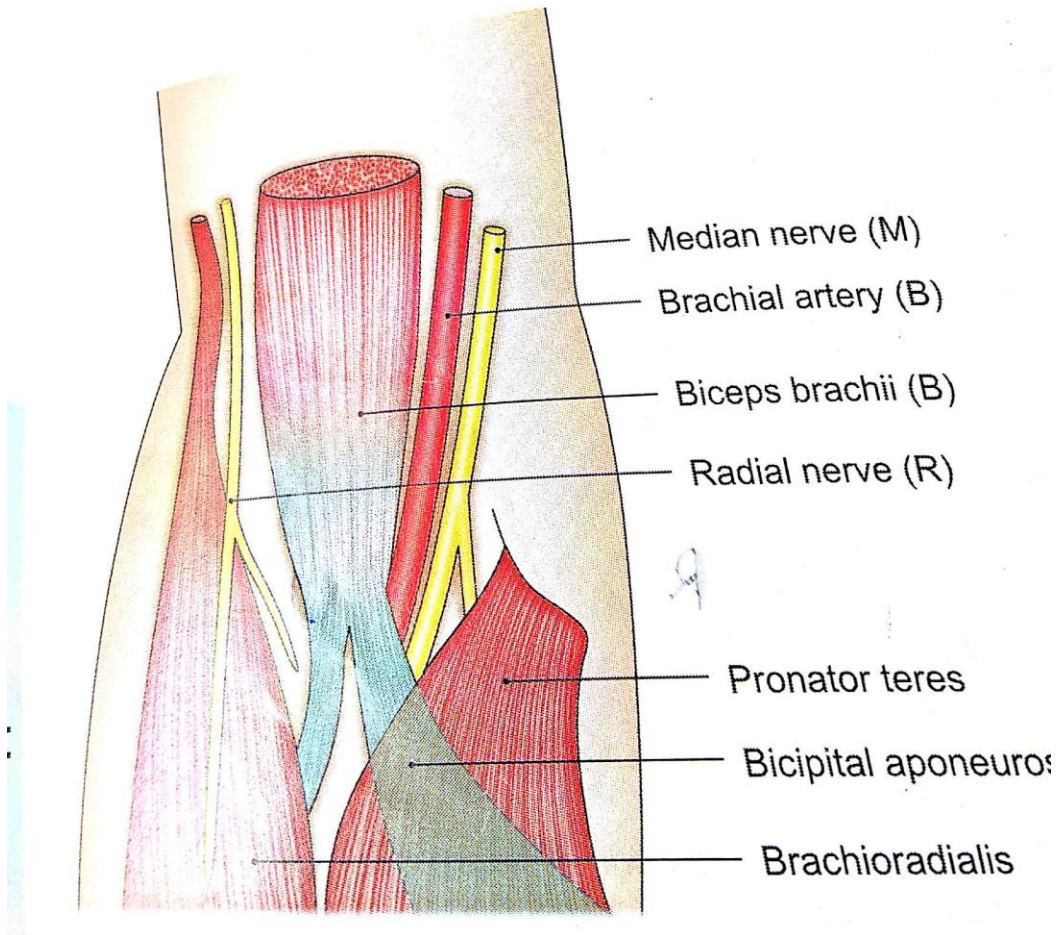
# Floor



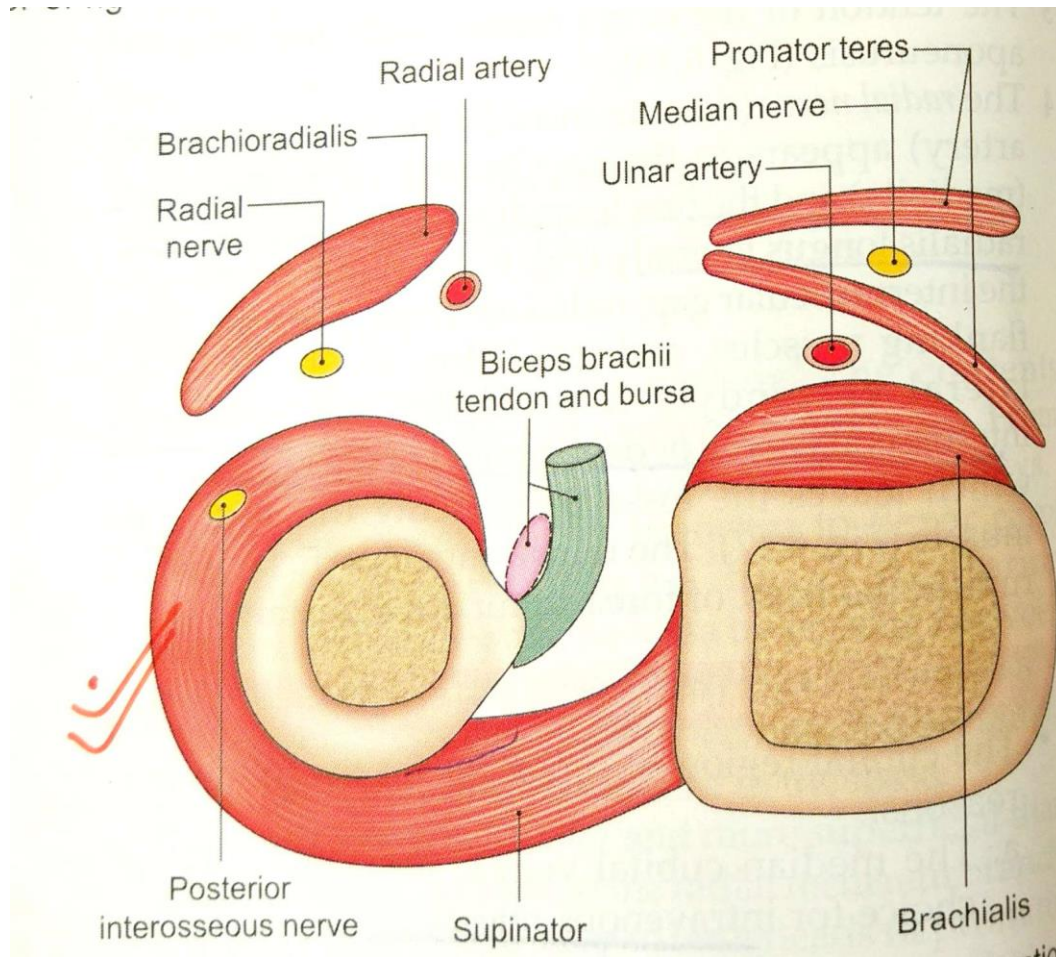
# Roof



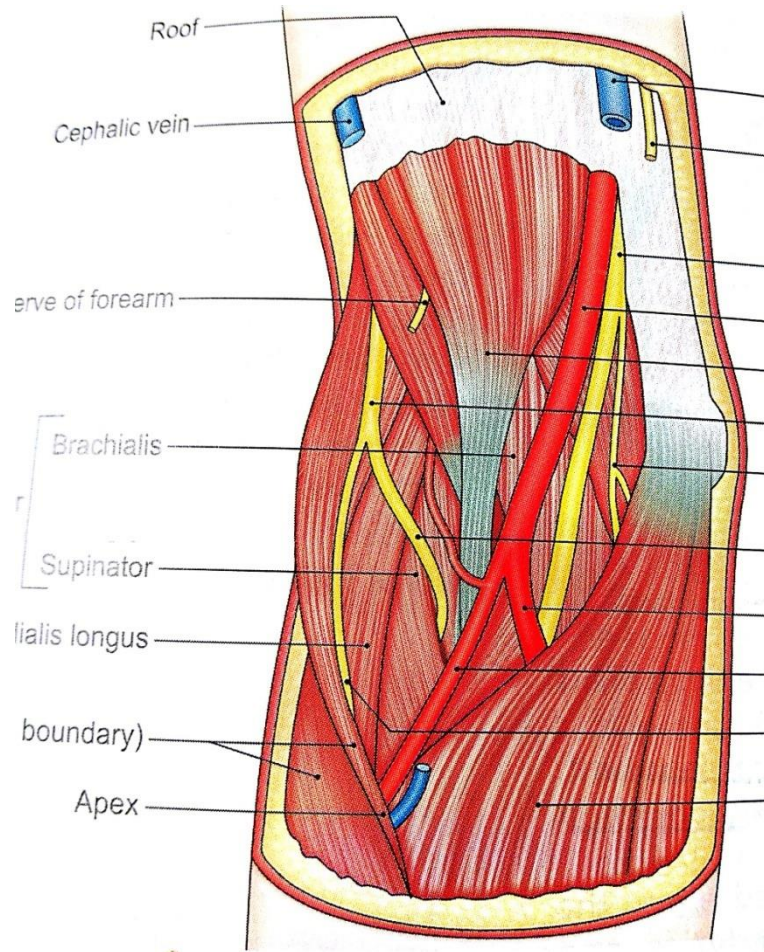
# Contents



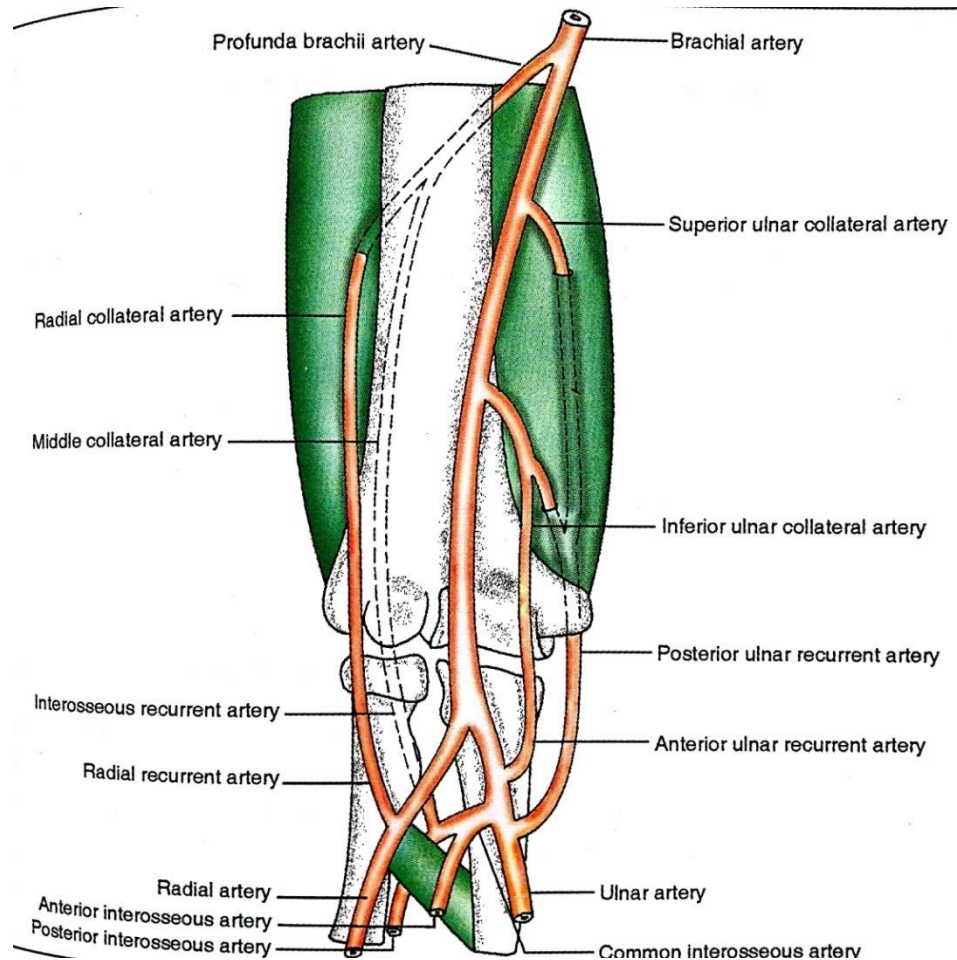
# Transverse section



# Cubital fossa



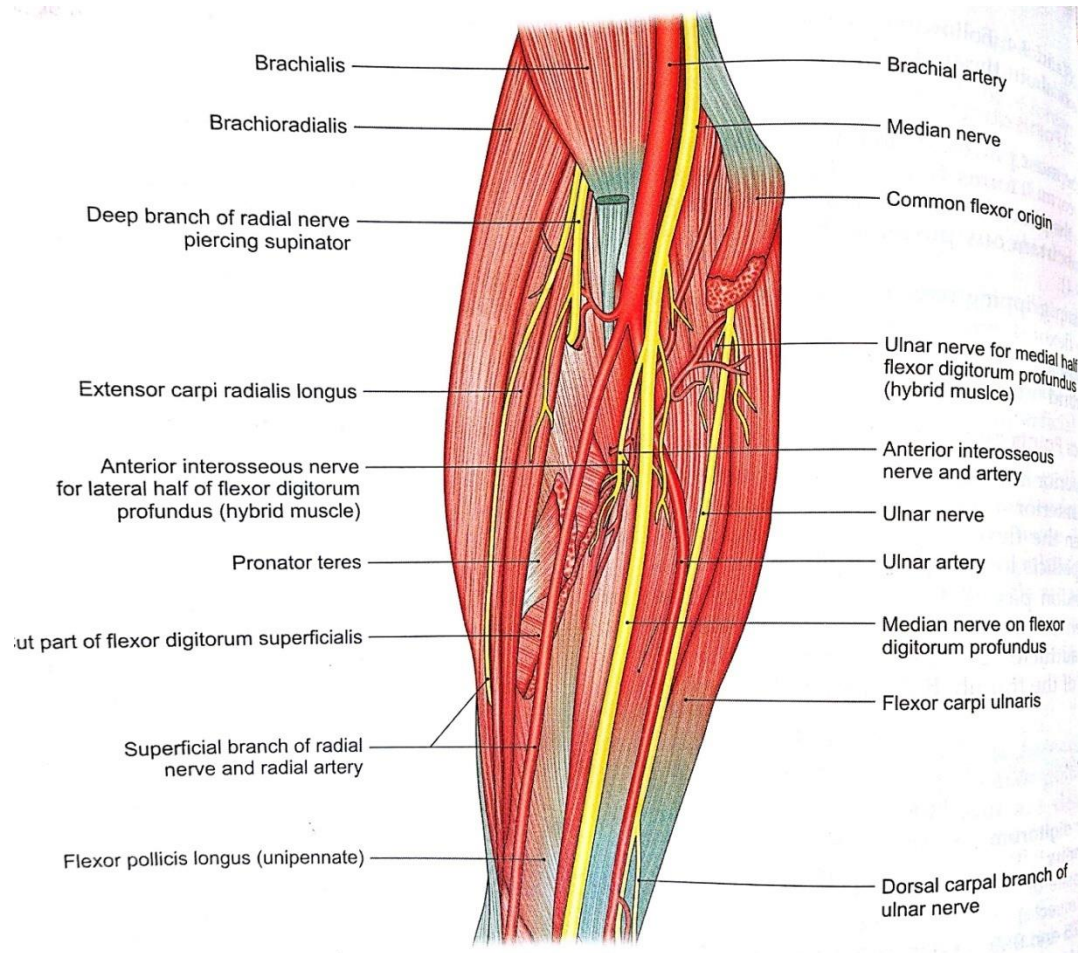
# Cubital anastomosis







# Median nerve



- Formation

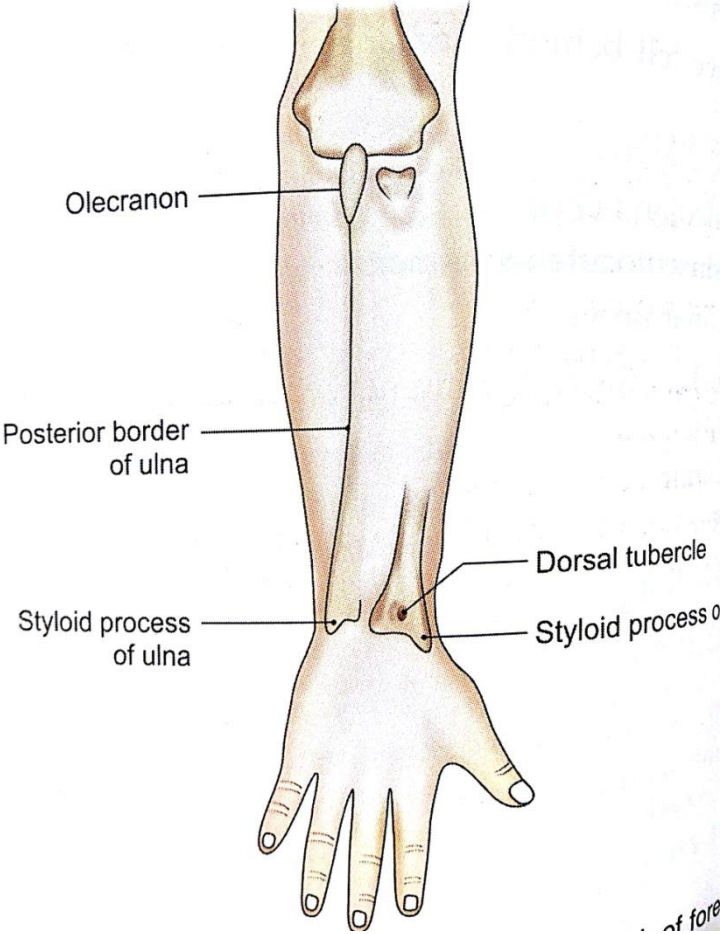
- Root value-  $C_{5,6,7,8}$  &  $T_1$

# Course

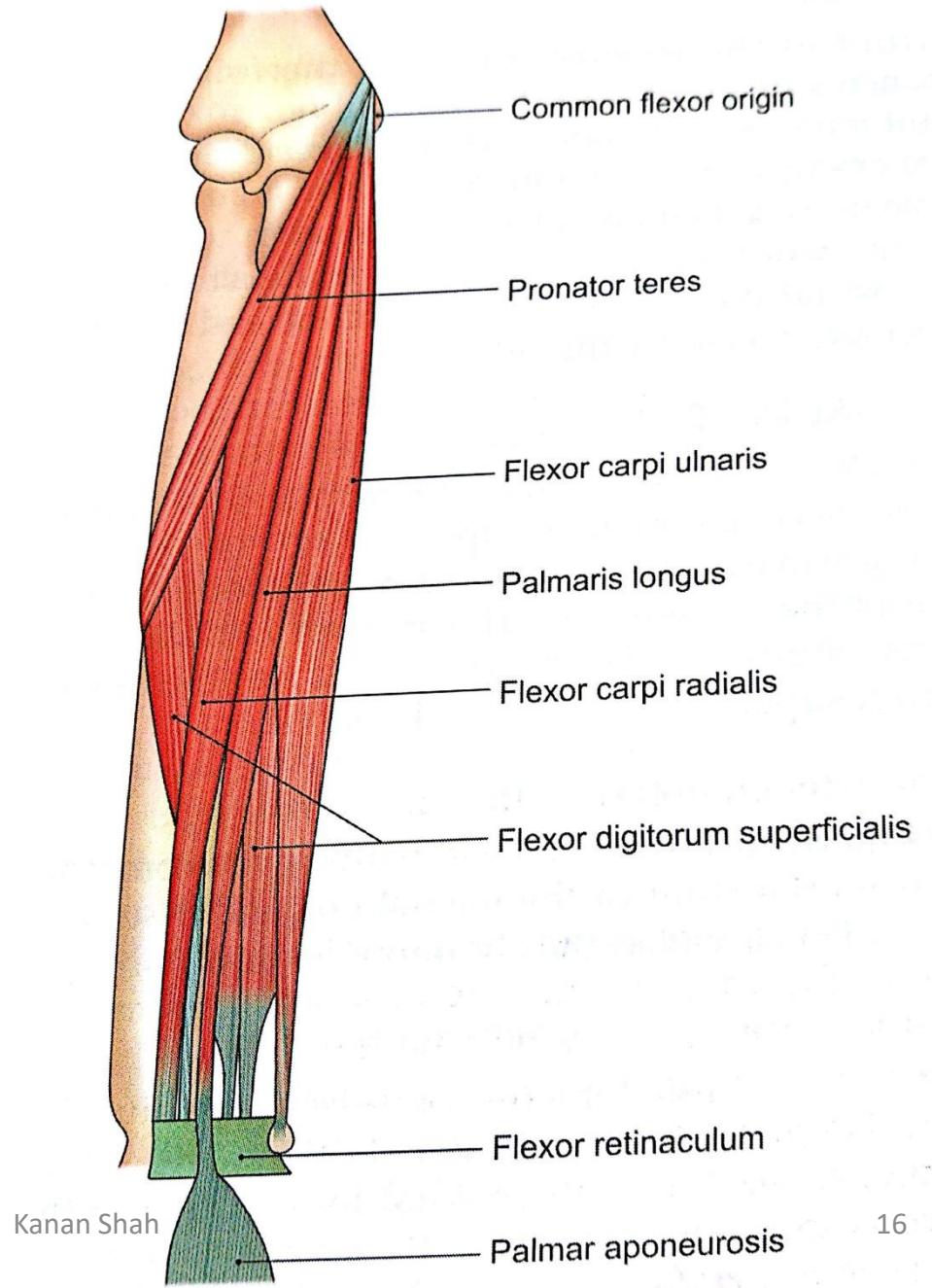
# Branches

# Applied Anatomy

# Flexor compartment of forearm



# Superficial muscles



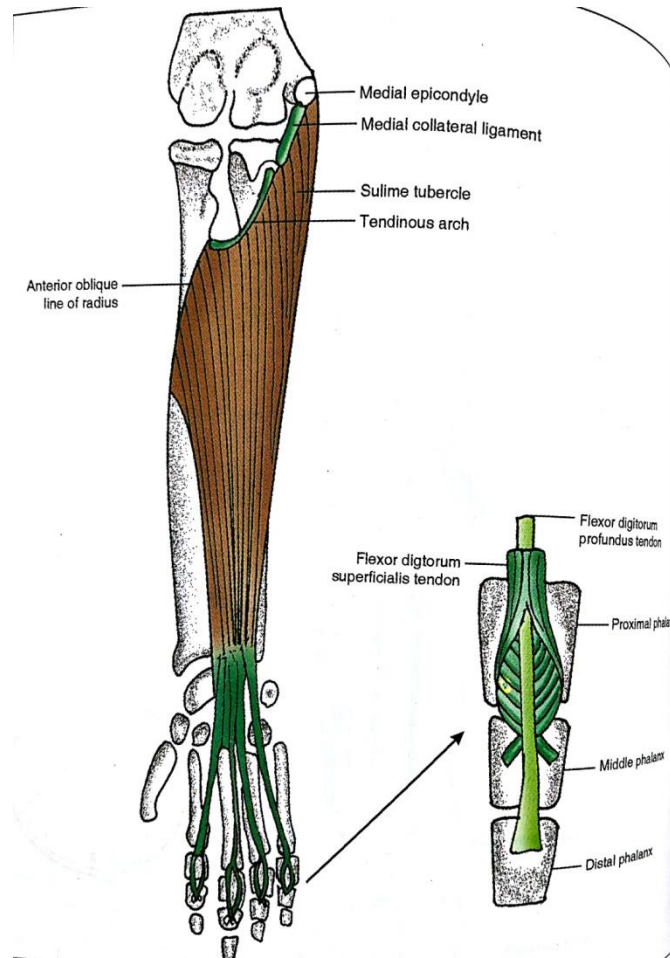


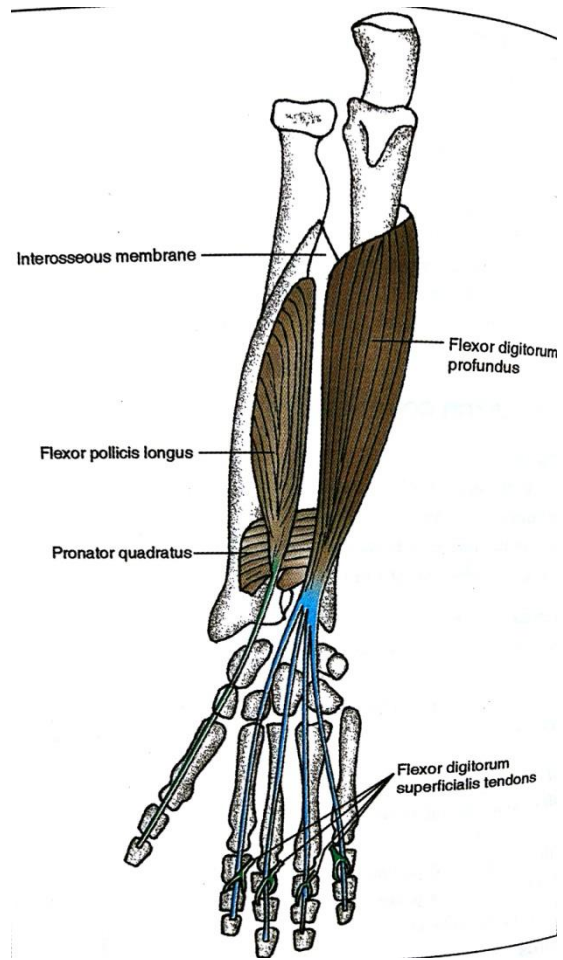
# Pronator teres

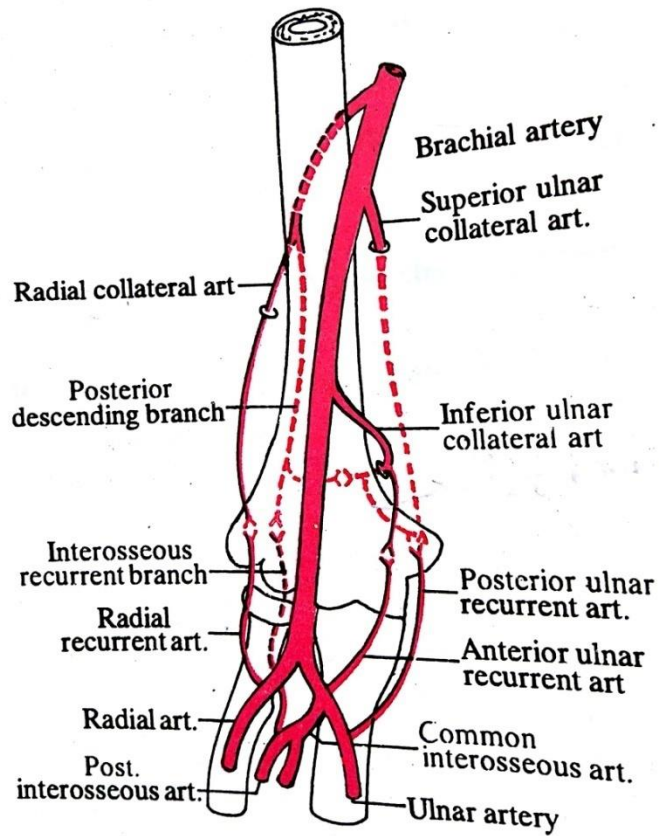
# Flexor carpi radialis

# Palmaris Longus

# Flexor digitorum superficialis







# Aknowledgements

- Human Anatomy by BD Chaurasia
- Gray's Anatomy
- Essentials of Human Antomy: Upper Limb and Lower Limb by Asimkumar Dutta